"Record of Tumors"

An Inaugural Dissertation

"The Record of microscopical Observations of One hundred Tumors"

Submitted to the Faculty of

Jefferson Medical College

For the degree of "Doctor of Medicine"

by

J. R. Wistar

of Phila

January 27 1852

It is only since a comparatively recent period, that the microscope has been made applicable to the study of morbid growths; and although many observations have been made, and a number of excellent works, published on this subject upon the Continent of Europe; still it cannot yet be said, that the morphological arrangement of tumors; more especially of those which are classed under the general term malignant, have been sufficiently elucidated. The diagnosis of such growths has ever been an object of much study and interest to the Surgeon; and any means which can assist his diagnosis, or verify it, subsequent to operation, deserves his most careful consideration.

Is not the microscope subservient to this most important end? Inasmuch as this subject is beginning now to occupy the minds of the profession generally throughout this country, I shall make no apology for adding the Record of the comparatively few cases I have had the opportunity of examining, to the general stock of Information; in the certain Expectation, that at no distant day; the careful and continued investigation of this subject, will be attended with results, highly important, not only to pathologists generally; but more Especially to the practical Surgeon. The study of the pathology of tumors and of fungoid growths is at present but in its infancy; the only basis of classification hitherto adopted,

has been that afforded by the peculiarities of external appearances, and of the appearances of sections as discernible by the unassisted eye; but these are not sufficient; the transitions into each of those general mechanical differences, which the exterior and interior surfaces of morbid growths present are so numerous, that the observation of these alone is not sufficient, either for diagnosis, or for after-certitude; we must go farther and call in the aid of the microscope;

During the last two years, my attention has been turned to the study of the microscopical elements of tumours, and it has seemed to me, that I could not choose any subject more fit; for

the inaugural dissertation, than the Record of these observations, a faithful one, I can at least promise it to be.

I am aware that such observations, are by many considered fruitless, and unprofitable, but for my own part, I do most sincerely believe, that so useful, nay, necessary an instrument has the microscope become, that ere long, it will occupy a post of honor in every Surgeon's study.

From time immemorial tumors have been divided into two grand divisions; Malignant, or Heterologous tumors, and non-Malignant, or Homologous tumors. Under these heads, divisions, & subdivisions, without number occur — Now what do we

mean by the term malignant? No term in all science, has been so much used, and I may say so much abused, it is in the mouth of every one, and how few are there that can define it? The word "malignant" has generally been attached to any disease or growth, "which continues to make progress in spite of all the efforts of the physician or surgeon"; perhaps it would be more correct to adopt the definition of Dr. Bennett, and say that the most accurate meaning of the term malignant, is "that which ascribes it to a growth, having the power in itself of redevelopment, that is, once existing, it may spread to

other tissues, or organs, causing in them a disease or growth, similar to itself, and analogous to that possessed by animalcules, or vegetable fungi." It has always seemed to me that too-many divisions are made, that a subject is rendered difficult of comprehension by too-great attempts to simplify; no two cases, are exactly alike, and if we attempt to bring every case strictly under division or rule; we might continue our sub-divisions ad-infinitum. It is, as Müller says "It is important to see much, ~~and~~ in order, not to lay too great stress on accidental varieties, certain peculiarities continually recur, and I have arrived at the

conclusion, that in all these structures, there are constant differences, which may be recognized with certainty."

If we bear this last sentence in mind, we shall be able, safely to steer through the sea of contending opinions. It is needless for us, to blindly believe, in the Existence or the non-existence of a cancer cell of such determinate shape, and size; let us look for ourselves, and if we do so, I am sure that no faithful observer, of many specimens will rise from his task, without verifying the ~~truth~~ of the sentence that there "are constant differences which may be recognized with certainty. Vogel's division of tumors, founded on their microscopical characters

seems to me to be the best of any of the divisions I have yet seen; Strange to say, he has however omitted the class of Epithelial tumors.

His division stands thus.

Non malignant	Malignant
1. vascular Tumors	1st Group. Deposits in 1. Typhus, 2. Scrofulosis, 3rd. Tuberculosis
2 Fatty "	
3 Fibrous "	
4. Cartilaginous "	
5. Osseous "	
6. Melanotic "	
7 Gelatinous "	
8. Encysted "	
Here I would add the class of Epithelial Tumors. Ibid	2d Group. Cancer: 1. Fibrous cancer or Scirrhus, 2. Encephaloid, 3. Gelatinous or Colloid, 4. Melanotic

Let us consider each of these groups separately, and first then of the vascular Tumors. (Synonymes

Aneurism by Anastamosis, Naevus, Erectile tumors, Hematoma &c.] These tumors are simple in their character, and easily understood; offering but little to ~~reward~~ our microscopical observation, they are composed of merely dilated capillaries. The fine vessels may be distinctly made out, if examined by a low power of the microscope. Care should however be taken; not to confound these tumors, with malignant growths, which may be well supplied with blood vessels. M. Robin has described a case (Lebert's Physiol. Pathol. T. ij, p. 99 & Pagli, Lec. Clinics &c. p. 87.) of Erectile tumour in which little cuts-de-sac, existed along the whole course of the artery; capable of being filled, and then emptied of their sanguine contents—

Next in our arrangement, stand Fatty tumours. These by the older writers are divided into Lipoma, cholesteatoma, and Adipose cysts. Purely fat tumors are generally easily discernible by the naked Eye, but not so in the more complicated forms; here, accidental causes, prepare, and the presence of fibrous tissue; renders a resort to the microscope indispensable. The common External characters of the ordinary fatty tumors are so well known, as to need no description; under the lens, we find the fat vesicles in a normal state that is in most cases, e.g. in the Lipoma and cholesteatoma above alluded to. these fat vesicles vary in size from the $\frac{1}{200}$th to the $\frac{1}{600}$th part of an inch in diameter, and

are composed of a cell wall, amorphous in its character, which encloses the free fluid fat, the olein. By many writers, and among others, Vogel and Bennett, these fat-cells, or vesicles, are said to possess a nucleus; this is not however a proper term, that darkened, opaque, and flattened so-called nucleus is in reality composed of nothing but crystals of margaric acid, the formation of which I attribute to chemical, and often I believe to cadaveric changes.

The nuclei, formative in their character, they certainly are not. Fatty tumours always possess an investing fibro-cellular capsule, well supplied with blood vessels; this capsule is composed of the fibro areolar tissue

tissue of the part, in which the tumor is developed, and serves as a bond of union to that part. In this capsule the vessels supplying the tumor ramify, and are so carried to their ultimate distribution. Fatty tumors do not occur, alone, there is always more or less proportion of fibrous tissue present, when this proportion is large, it is often difficult for us to say, to which class exactly the tumor belongs, indeed we cannot say that it belongs wholly either to the fatty or fibrous class, one, or to the other, for while externally presenting all the characteristic marks of a hard fibrous mass, it may yet prove on microscopical investigation

to be composed, merely of fat vesicles pressed down in layers, resting one upon another. For my own part I believe that fatty tumors, often do degenerate into those of a fibrous character, for we know that if fat vesicles be placed under the compressor of a microscope, the wall of the vesicle will be ruptured, and the free fat escaping as oil globules, the vesicle wall, which I suppose to be not amorphous but fibrous, will remain. If therefore we have pressure exerted by the tension of integuments, such partial transformation of a fatty tumor can easily be conceived of as taking place; and more than

this, it seems to me that the occurrence of adipose cysts may be explained on the theory – I have seen several instances in which the female breast has been removed and on ocular examination, pronounced to be a sero-cystic tumor, and yet, neither were the apparent cysts, true cysts, nor were their contents serum; the walls of the cysts under the microscope proving of a coarsely fibrous character, and destitute of any epithelial membrane; showing these cysts to be not secreting, in their character, but acting as reservoirs. – their contents, varying in color from yellow to dark purple, and black, were nothing but oil, and granules

chrystals of margaric acid and fat being dispersed throughout the whole mass, no vestiges of a secreting membrane, (Epithelial in its character) being visible. I have several such specimens in my possession now.

Jennett mentions the presence of fatty granules, and chrystals of cholesterine in atheromatous deposits on the arch of the Aorta, I have seen the same thing, not only in the aorta, but also in the semilunar, and auriculo-ventricular valves. With regard to the two divisions of Lipoma, and Cholesteatoma, I believe that their difference is the result of a mere accident, viz pressure. Müller in his work "Über die feinen bau, und die formen

der Krankheiten Geschwülste" draws a line of distinction between these two classes; Cruveilhier in Anat. Path. liv. ij. tab. vij does so also.

Müller says "The cellular tissue bears no resemblance to the adipose cellular tissue in the healthy state ... The (i.e. fat) cells are irregular in form, as in those of the sheep, some being pentagonal, others hexagonal &c. in form ... the fat is more solid like tallow" &c. I have examined several cases of what I presume to have been Cholesteatoma and I must confess that I have not been able to notice the peculiarities described by the above authors, or at least

to the same extent; certainly none that I have been desirous to be classified in a separate group, it seems to me (and I say this with all deference to high authorities) to be a complicated simplification so to do —

We next come to consider the general class of fibrous tumors, which I would define to be tumors composed of fibrous tissue (yellow or white) in any stage of development; including in this general division the fibro, nucleated, or fibro-cellular, of Paget, and the fibro-plastic of Lebert — in the most perfect form of fibrous tumors I mean those

in which the fibres are fully formed & in which we have an absence of the fusiform cells; we find upon measurement that the fibres vary greatly in size, from the 1/4000th to the 1/8000 or 1/10,000th part of an inch in diameter. The yellow fibres are rather larger than the white. The white fibrous tissue in some instances is collected into bands, but more generally it forms a close net work, somewhat like the ordinary areolar tissue, the areolæ however being very much smaller. Sometimes these bands take a semi-circular, or even a completely circular form;

The yellow fibrous tissue on the contrary is collected into many-bands, or else the fibres curl in every direction, very much like the horse hair stuffing of cushions — in most tumors; these two fibrous tissues are combined, perhaps, it were better I should say, that (we always need the white tissue occurring with the) although we have tumors composed of white fibrous tissue occurring alone, still I have never seen the yellow tissue occurring independently of the white, speaking generally I would say that these two forms of fibre, mostly occur together

It is very easy to distinguish them by a glance at the microscope. Now what do he mean by the fibro-plastic growth first described by Lebert?

As I understand his description, it would seem that he would convey the idea, that the term fibro-plastic, should be applied to those cells, nucleated of course, and to those free nuclei which go to the formation of fibre - either white or yellow, so that a fibro-plastic growth would be a fibrous tumor in process of advancement; the French fibro-plastic cell, being the same as the fusiform corpuscle

of the English microscopists.
These cells are long oval
nucleated, caudated, cells
very slightly granular, or
at least slightly dotted
in their appearance, they
may be oat-shaped, or even
angular & oval in their form.
These tumors present most
generally a hard resisting
feel, although sometimes they
may be so Elastic, and doughy
as to lead to considerable
Error in diagnosis. When
cut with the knife, they
appear pearly white, & hard
more or less nervous, may
often be seen coursing through
them. Vast quantities

of oil and fat, are always found in connection with fibrous tumors. very often we have adipose cysts, which I have described when speaking of fatty tumors, & of which I give several instances. Fibrous tumors ~~are~~ always possess a species of capsule of areolar tissue attaching it to ~~that~~ part of the body in which it may be located.

Sometimes from the very position of the growth, ~~the~~ it may seem to acquire peculiar characters, as for example in those hypertrophies of the sheaths of nerves, in which we have

a species of neuroma developed.

The whole subject of neuromatous tumors etc is very much confused, no two writers agreeing — Now I would define Neuroma to be any growth within the neurilemma of a nerve, this growth occurring in two different ways. Either by the hypertrophy of the inner layers of the neurilemma, or else by the deposit of peculiar cells, between the fibres of a nerve. Subcutaneous painful tumor is merely a fibrous growth, a hypertrophy of the skin, which produces its characteristic pain by pressure upon a filament of nerve. In tabular form

Neuroma proper	1. By hypertrophy of neurilemma.	
	2. By deposit of true cells between the nerve fibres	
Subcutaneous painful tumor	1. Fibrous growth presses the filament of nerve	

We now come to consider a new class of tumors, viz, the Cartilaginous, these are comparatively rare, rarer than would appear from a cursory glance at the subject. These growths are often compounded not only with fibrous growths, but also with old Epithelial formations, so that indeed I believe it to be absolutely necessary to use the microscope, before coming to any positive conclusion. To this class of tumors Müller, the first who really, and satisfactorily investigated this, has given the name of Enchondroma a name which has since been almost universally adopted by writers in all countries. What I must

We understand by this term simply "that the growth is formed mainly of a true hyline cartilage" — Generally we find such tumors are connected with the joints, often however they are met with in the soft parts, &c. (for a full history of this subject see Paget's lectures p. 61. London Ed.) It is only with the microscopic characters that I have now to deal, and these are found to agree pretty much with those of fœtal cartilage. A variety of cartilage cells, of every variety and shape and size, arranged in various manners. Having not however had an opportunity of examining very many of these specimens I do not feel competent to discuss the general histology of these growths, those desirous of studying the

subject are referred to Müller's work on Cancer p. 149. S. Jac. Hertz. De Enchondromata 1843. Rokitansky. Pathol. Anat. Band. 1. p. 261. Lebert, Bennett and others. — Osseous tumors I shall also dismiss in a few words, inasmuch as I know but little about them. A description will be given of each case that I have seen, and I will not therefore generalize.

Melanotic Tumors I believe to be a false division. I have never seen any, deserving exclusively that name. Melanosed fatty, fibrous, and cancinomatous tumors I certainly have met with, but I am inclined to look upon the mere point of pigmented cells as merely a complication of the original growth, I would surely

We make an other subdivision.

Next let us look at Encysted tumors, divided by Vogel into True, Simple Encysted T. (Tum. Cystici), and the comp.d; combinations of this with other forms of tumor, (cystoids) — "True Simple Encysted tumors, are those possessing a perfectly closed membranous sac, whose contents are imperfectly, or not at all organized". Under this class we have two subdivisions.

1. Simple cysts containing serous, & aqueous contents
2. " " " " thick cheesy contents, E.g Epithelial scales, fatty matter of all kinds, Crystals of cholesterine, margaric acid &c., Teeth, Hair, & many other ~~abnormal~~ products are often found —

The Cystoid T. the Compound Cystic T. are those in which we find, a cyst, or

Cysts developped within the sac, or the wall of the primary, enclosing cyst.

Paget (p. 13) divides cystic T. or Cysts into 1st Simple or Ovarian cysts, containing fluid or unorganised matter & 2d Compd or proliferous cysts, containing variously organised matters.

Cysts may be supposed to have three modes of growth, or rather of origin. 1. By fluids accumulating in areolæ, in fibrous & other tissues.
2d By the dilatation of ducts, E.g. Sebaceous cysts (in some cases), lactiferous cysts, and to a certain degree ovarian cysts — 3d are those of Eventually morbid growth, from neoformed Elementary structures. The investigation of this 3d. class of cysts is full of interest, and I may also say of

difficulty - I will now subjoin Virch's division of cysts.

1. Simple or Serous cysts. - (containing fluid or inorganic matter)

1. Gaseous cysts - (see Hunter's works. vol. IV. p. 98. & pl. 37)
2. Serous cysts.
3. Synovial "
4. Mucous "
5. Sanguineous "
6. Meconium " {mingled with Epithelial scales & chyle & of Cholesterine &c}
7. Colloid " of the Ovarium - doubtful as non-malignant -
8. Cysts formed by dilatn. of ducts, orifices &c.

2. Compound or Proliferous cysts.

1. Cysts with other C. growing in or upon their walls (see Hodgkin's descrpn. of Ovarian C.)
2. " " vascular growth from walls of internal surface
2. Glandulifer cysts.
3. Cancerous cysts. (Recurring cysts)
4. Cutaneous proliferous C. (h. ovarian &c.

In describing cases I shall allude to this division -

Here Vogel's division of non-malignant tumors ends. He makes no mention of Epithelial growth,

pose, after a most careful search, I am not aware that either any English or continental writer has at all discussed this subject — Rokitansky alone notices them in his "Handbuch der allgemeinen pathologischen Anatomie" p. 383. he says "that although their formation is often only local, yet that they correspond so entirely with Cancer, that writers include them under that subject, &c. &c."

The subject of Epithelial Tumors, having been chosen by my fellow student Mr. da Costa, as an inaugural thesis, & as it is one to which he has given much attention, I shall not enter into any of the particulars as to the origin, mode of growth &c. of Epithelial Tumors.

We have now arrived at the great class of Malignant tumors. & without paying attention to the deposits included in the first group. I will pass at once to the consideration of Cancer or Carcinoma

The innocent tumors, the non-malig. tumors, present but comparatively few difficulties, to the investigation of the microscopist; but so however with Carcinoma, here all is darkness, and uncertainty, little has yet been done towards rending the veil of obscurity, which has for ages overhung this dark and most terrible disease; its diagnosis is still uncertain, its treatment, yet more so, and the great question of the present day which forces itself upon the mind of the reasoner, and observer, is "What is Cancer? How shall we treat it?

Cancer is to be met with, in almost every portion of the human frame; we find it involving alike skin, mucous membrane, muscles, fibrous tissue, and bone, and even deposited in the medullary cavities of the bones. If then the question be put; "what are the elements of a cancerous tumor?" the answer must be a general one: "The cells of cancer infiltrated into the minute structure of any tissue." In examining therefore any suspected growth, it becomes necessary, for us to bear in mind constantly, the appearances presented by the part, not only when in a state of health, but also when affected by any other disease, which may yet be foreign to cancer.

How common is it to hear such remarks as the following from the lips of those, who are called, to use a common phrase "Believers in the microscope" or "You say this is cancer; now what is your standard of cancer? whence is it derived? What are your data? Have you any, or has it been arbitrarily assumed, that this is cancer, and that is not? Now these are natural questions, and should be answered. The only true and practical standard, is that deduced (is that deduced) from the careful and continued investigation, and examination of such cases, whose malignancy is undoubted, those cases which destroy life either directly, or by returning after repeated

Extirpation. Now it will be found that all those who have made this subject practically, their study; will as the result of their own investigations, establish for themselves a standard of their own, and moreover if the results of all experienced modern observers, be compared together; it will be evident that although they may differ in minutiae, they still agree on the main, important, and practical points.

What is the progress of Cancer? and first of its origin.

The majority of facts, with which we are acquainted, lead to (suppose) the belief that the elements of a Cancerous Growth (I mean those

cells, filaments, and granules) originate in a coagulated exudation poured out as all other exudations are by engorged capillaries, that is the common belief. But Velpeau is of opinion that cancer may exist primarily in the blood, and Virchow positively asserts (and his authority can scarcely be questioned) that in six cases he had seen cancer cells in large venous trunks, and he is therefore convinced that it may arise locally in the blood — Lebert & M. Nonat discovered cancer cells in the right iliac vein, these cells being similar to those found in other diseased tissue, and the walls of the vein being inflamed. But this evidence may be erroneous in some respects,

and even if correct, I do not think to be sufficient to establish the doctrine that cancer exists as positive cells, in the blood primarily; unless confirmed by future observation: if so, then we may suppose, that under some circumstances, the liquor sanguinis may act as a blastema as well within the vessels as without in. In cancerous exudation, the patients are generally of an adult or advanced age, the part first affected is generally a glandular or fatty organ, the lymphatic glands are attacked secondarily, (Bennett. p. 205) and the rapidity of growth is in direct proportion to the number of cells, which are very perfect, then it

some tendency to ulceration; when this does take place, we have the formation of fungoid excrescences – In tubercular exudation on the other hand, the patients are generally young, the part first affected is most often a lymphatic gland, afterwards the deposit takes place in the lungs, and on serous surfaces – There is not much tendency to cell formation, the cells are abortive; but there is a great determination towards disintegration, and ulceration. Take (pus as a) the products of inflammation as a standard (say pus) we would remark, that cancer is above, and tubercle below that standard i.e. Cancer is highest in the scale, then the products of true inflammation

and that the tubercular exudation is the lowest in the scale. — Now the cancer cells, and nuclei once produced, the cells propagate themselves, by the breaking down of the cellwalls, and the liberation of the nuclei, which form new cells. As a general rule the more cells in a tissue, the faster its growth, this rule applies also to cancer. Cancer is a growth, and vascular, tubercle is a deposit (one would almost think examination) & possesses no vessels. My own injections of two or three ~~tubercles~~ show this relative degree of vascularity most distinctly.

Cancer is said to be inoculable, but there is only one successful experiment (Langenbeck's) upon a dog; he produced the disease a

Rather I should say, the disease followed the injection of cancer cells into a vein — All other Experiments of a similar nature, have since failed in the hands of all Experimentors, and it is well worthy of remark here, that naturalists now state that cancer is as common in the dog, as in ~~the~~ man, so that such Experiments can not be relied upon — Perhaps it would be well, for me here to say a word with regard to Experiments of Dr Leidy of this city, some few months ago. He took a piece of fungus hæmatodes, fresh, and inserting it into the back of a frog, it united, and after the lapse of some weeks the adhesions were found to be complete; from this fact, many have inferred a confirmation of the result —

announced by Langenbeck; from this con-
-clusion I would beg to differ, the mere
fact of union having taken place, proves
nothing as to the disease; for Dr Leidy,
did not find the characteristic
cells in any organ, or tissue of the frog,
mere union alone resulted - Supposing
even, he had found, these cancer cells,
is not the frog of too low an order of
the animal kingdom, to draw any
deductions therefrom, respecting the
propagation of the disease in man?
- I think so - If cancer is
inoculable, by this home, either - I
myself or some of my friends would
have most probably been infected;
for my own part, peeling cut-
surfaces on my hands have
been exposed to the fluid of cancer

shown, and yet no irritation has followed. The generally received opinion now is that Cancer is not inoculable, and the simple experiment of Langenbeck goes for naught. "Cancer may degenerate, the cells receiving a check in their development, and becoming abortive, in other words a healing process takes place, the result being a fatty mass, a fibrous cicatrix, or a calcareous concretion."

This has been especially detected by Professor Rokitansky of Prague in 1845. His observations were I believe confined principally to the liver. Hence we need not always say, that "Cancer must be fatal"

Cancerous tumors may be arranged for the convenience of study into three classes; first, the Scirrhous, or hard Cancer; second, the encephaloid or soft cancer, and third the colloid or gelatiniform cancer; the first two forms seeming to differ from each other, only in the presence of a greater or less proportion of fibrous tissue, and also of cells; many fibres and few cells constituting Scirrhus, few fibres and many cells forming encephaloid. Scirrhus cannot be distinguished from fibrous tumors by the unassisted Eye, in reality it is only a fibrous tumor, with one element superadded, and that element is the cells of cancer; the arrangement of these cells is peculiar

The que Hematodes is merely a sprouting, or outgrowing Encephaloid.

they are infiltrated between the fibres of tissue, so that the name of "infiltrating growth" as applied to cancer by Dr. Walshe, is a strictly correct, and extremely forcible term. — The encephaloid, the cells are in great abundance, and the consequent proportionate absence of fibrous tissue, renders the whole tumor much softer, approaching in truth as its name imports a brain-like consistency. — Scirrhus and encephaloid may exist together, or Walshe's scirrhus has a natural tendency to pass into encephaloid, by the more rapid development of cells; so that we often find, both of these different forms of cancer, (if different they be) united in one and the same tumor. — The name colloid cancer is applied to those collections

of jelly, or glue-like matter, which occurs either in cysts, or between the fibrous tissue; in this colloid matter, acting as a species of blastema, the cancer cells are developed in the same manner as in Scirrhus or encephaloid — But little fibrous tissue occurs in colloid cancer.

The synonymes of Scirrhus are carcinomatous sarcoma, Schirrhus, fibrous cancer, & stone cancer; those of encephaloid, are medullary sarcoma, fungoid sarcoma, cerebriform cancer, soft cancer, spongy carcinoma, and many others too numerous to mention. While colloid cancer is described by writers, as gelatiniform and alveolar, or gum cancer —

I have now arrived at that very interesting, and puzzling question. Is there, or is there not a cancer cell? The Existence and non Existence of such a cell, has been an Apple of discord to all microscopical Observers; Some have answered positively in the affirmative, and others, equally as positive in the negative; to the question, Is there a true, distinctive, and always characteristic Cell of Cancer? For my own part I believe that there is a true cancer cell, but whether it is possible always to distinguish such cells, under all circumstances, with unerring certainty, seems to me to be another consideration. This

subject has however been so well treated by Lebert in his "Traité pratique des maladies cancereuses, et des affections cancéreuses, ou de cancer" that I may well be excused for translating immediately – "If the question be put in the following terms, "an isolated cell being given, is it possible to determine by microscopical observation, whether or not that cell belongs to cancer, we would not hesitate to answer in the negative; but the (problem) we have always sought to resolve, is that; not an isolated cell, but a tissue being given, is it possible to determine by microscopical inspection, if that tissue is cancerous, or not? To this query we would not hesitate to answer in the affirmative; always however

making the reservation, that there are exceptional circumstances, (which we will discuss hereafter) in which microscopical examination alone (would (may be) remain) insufficient" --- In another portion of the same work, he adds "We have already insisted at length on our Physiol. Path. on the specificity of the cancer cell ---- and again "The type of the Cancer cell, is a small, regular, sphere, with an elliptical nucleus eccentrically placed, occupying about one half of the interior of the cell; and containing one or more nucleoli; but this type is not often pure, the cellular envelope takes the ovoid, triangular, heart, and candate shape ..... It would

be useless, to recount here all the shapes assumed by the cancer cell, it is sufficient to remark, that in no other cell do we observe this multiformity of the cell wall to the same degree.....

The nucleus, as we have already seen, the constant element of the cancer cell.....

Now it appears to me, that this little extract from Lebert (published only some three or four months since) contains (the whole) all of the essential points, relative to this much discussed, and much abused subject the cancer cell. — I have endeavoured in the foregoing pages, to give a short account

of the present state of our knowledge of morbid anatomy; as derived by the means of the microscope. Theorizing is at best, dangerous to truth, I have therefore avoided it as much as possible, and have stated the views of our best and soundest observers. From the very nature of the subject, I have been obliged to quote largely; but I preferred doing this, to incurring the blame of those, who generalize, without either sufficient thought, or observation. —

In the remainder of this little paper, I subjoin the record of my own observations. these at least I can promise to be both original and faithful. — — —

Record

First division - Non malig.t Tumors

1st Group - Fatty Growths.

Case - Thos. Calahan. Æt. about 40.

has had steatomatous tumor on arm for some months, immediately on the deltoid muscle. The tumor was about as large as an hen's Egg. Removed by Dr Miller at the Clinic of Jeff.n College Oct. 19th 1850.

Microsc. Examin.n - This tumor was in every respect a normal fatty Tumor (if I may use such expression). The fat vesicles or cells were about the 1/500 or 1/1000th part of an inch in diameter. a great many free ~~fat~~ oil globules were floating about. Fibrous tissue was also present to some extent - The Tumor was surrounded by the usual capsule of "fibro cellular tissue"

See plate 1. fig. 1

I am indebted to the Trustees of Mr. J. C. Morris for an opportunity of Examining this Specimen.

Case. , 1837 Oct. 8th Dr. Gibson, at University, removed from neck a fatty tumor. This tumor on microscopical Examination showed the usual fat vesicles &c, but many of them possessed this peculiarity by the presence of Chrystalline nuclei of margaric acid, assuming a stellated form, varying in size, some occupying the whole interior of the cell, while some existed as mere points. These Chrystals were in some instances also deposited on the External surface of the cell wall. Fibrous tissue, and fat oil globules were also present to a great extent, the latter resulting from the bursting of the walls of some of the vesicles, and the consequent escape of the oily contents. See plate 1 fig. 2.

Case — E. G. M. Æt 48. unmarried,

had experienced for several months prior to last June, occasional pains in the right breast; about the commencement of that month, a hard lump could be felt on examination, which gradually enlarged until the early part of July, when it was removed by Dr Parcoast. The wound healed kindly and the patient is now entirely recovered. — The breast when removed was of a medium size, and seemed to consist of a hard fibrous tumor, enveloped in a thick layer of fat, presenting to the view internally, numerous dense, nodulated bodies, of the almost cartilaginous consistency, crunching under the knife when cut; ~~there~~ several cysts were also seen, filled with a thick, oily, fluid, varying

in color from a dirty brown to a purple hue; these cysts were of different sizes, some being only as large as a pea, and others double and treble that size. A section made completely through the tumor from without, revealed the following structures; Next to the skin, a layer of fat; then a hard flattened, fibrous mass; then the dense nodulated bodies above alluded to, and lastly a layer of tissue; somewhat hard in its character, and apparently fibrous, containing the cysts. The layer of hardened tissue immediately adjacent to the superficial fascia, proved when examined by the microscope, to be fibrous; the fibres interlacing closely one with another. By the addition of acetic

acid, the whole mass was rendered transparent; and scattered throughout might be seen numerous, elongated oval nuclei about the 1/1500th part of an inch in length, and about the 1/4000th part of an inch in breadth, — (see plate I. fig 3. a). The nodulated masses presented the same fibrous appearance; no nuclei could however be detected even after the addition of acetic acid. The mass in which the cyst occurred, and which was situated directly above the great pectoral muscle, proved, upon examination, to be composed of merely condensed adipose tissue, the fat vesicles being flattened & arranged in laminæ, the one upon another, giving the whole a somewhat fibrous appearance. Many of the fat vesicles contained chrystalline, flattened nuclei (b)

of manganic acid. I use the term nuclei in the sense defined heretofore. In some instances the crystals seemed to be deposited on the external surface of the vesicle. The cysts, which were filled with an oily fluid, were surrounded by fibrous walls, and I was not able to detect, even after the most careful examination, any vestige of a secreting lining, epithelial membrane.

The contents of the cysts consisted chiefly of oil globules, but there was also a considerable quantity of granular matter. (C) The substance of the mammary gland, seemed to have been almost entirely absorbed; very few of the glandular cells could be detected, and those were ~~situated~~ only in the anterior portion of the breast; in this

Region, the galactophorous tubes remained in a healthy condition. — An analogy has been pointed out by some of the modern German writers, between cirrhosis of the liver, and that condition of the mammary gland, here described, in which we have great and hypertrophic development of the fibrous sheath of the gland, this sheath covering not only the external surface of the gland, but also sending in throughout its whole substance prolongations of this membraneous fascia, permeating that substance in the same manner as the capsule of Glisson does that of the liver. — The same causes acting upon analogous tissues, will produce like results; the development of a fibrous tumor, causing atrophy and absorption of either glands. — The occurrence of the

ity cysts I would explain on the principles laid down in the introduction to these records.

This ~~[illegible]~~ case is reported at length in the Medical Examiner Decr. 1857. —

— " —

Case. Plate 1. fig. 4. shows the appearance presented by a fatty tumor, about the size of a large pea, removed from the face of a student of medicine by Dr. Mütter, May 15th 1856. The normal fat-cells of large size, about the 1/500th to 1/300th part of an inch in diameter.

— " —

Case. at mos. has had a congenital tumor on the back of the thumb of the left hand. The case was brought to the clinic by Dr. Pirkingham and was operated upon by Dr

Mütter at the clinic of Coll. Med. Coll.
The tumor was found to be adherent to the periosteum of the metacarpal bone of the thumb - Upon microscopical Examination I found the tumor to be composed of fibrous tissue, interspersed with numerous masses of fat vesicles, the fibrous tissue was for the most part of the yellow variety - (See plate 1. fig 5)

Upon the addition of acetic acid I thought I was able to distinguish some fusiform corpuscles, going to the formation of the fibrous tissue but of this I will not be certain - Examined Externally this tumor presented a soft, doughy, elastic feel, so as almost to convey to the Examiner the idea of a cyst. The wound healed kindly.

Case. — M. Y. L. æt 27.

Dr. Müller at Clin. of Prof. Medley.
This tumor was situated upon the left posterior scapular space, and was as large as an orange. and lobulated in its character, with the usual investing sheath of fibro-cellular tissue. The fat cells presented only the peculiarity of changing of margarin acid, both internally and externally (See plate 1. fig. 6).

Case. Mrs Wegandt at about 50 Yrs had a tumor in breast (the left) for some ten or twelve months, with shooting pains &c. — The tumor was removed by Drs Müller and Vancourt May 12th 1857. The axillary

glands of the same side being hard-ened and enlarged, they were also removed. Upon an Examination of the breast microscopically, the appearance presented, was so exactly similar to that of the breast removed on July 8th by Dr. Pancoast, and reported at page , that I have not consid-ered it worth while to make the drawings very full. plate 1, fig 3 answering for both. The patient recovered, the wound healing in 10 days, and is now quite well. Perhaps however I had better " insert the proper plate as taken from the case. See plate 2. fig. 3.

"

2d Group. Fibrous tumors.

Case. A. M. æt 60. Has had a tumor existing on the plantar fascia, as a hard ballon, like body for many years, but it was only a few months prior to its removal that it occasioned any inconvenience. It then began to enlarge rapidly, and attained nearly the size of a walnut. The tumor was closely adherent to the skin, which was with difficulty dissected off, and appeared to be of unusual thickness. Upon placing a section of the growth under the field of the microscope, it was observed to consist of a fibrous tissue, or rather of bands of ~~fib~~ tissue, the bands in some instances running side by side in a wavy manner, and in others interlacing one with another. The fibres when separated by the use of the needle, appears to partake of the character of yellow fibrous or elastic

tissue. Here & there might be seen the fusiform corpuscles described by Lebert, and Bennett, which were composed of a simple nucleus, with two caudated extremities, the nucleus being about the 1/3000th part of an inch in diameter. These fusiform corpuscles by their juxtaposition evidently went to the formation of fibres. Fat vesicles, & free fat globules were to be found in abundance throughout the whole tumor. (See plate 2, figs. 1 & 2)

Case. Henrietta Williamson æt. 18 (negro)
Has had for several months a hard lump forming in the pendulous lobe of the left ear, producing some little pain. This was removed by Dr. Tomlin at clinic of Jefferson Med. College Nov. 9th 1870. Microscopic Examn. showed the mass to be nearly fibrous. See plate 2 fig. 4. This case has been reported

by Dr. Heller in the "Neue Amerik. Monatschr. für Natur- und Heilkunde," Dec. 1830, p. 225.

Phil. This tumor of the Ear, is somewhat rare, occurring only I believe in negroes and anemic, never in the white.

Case. X. Y. Z. a Sailor, at the Marine hospital, died with all the symptoms of cancer of the stomach. This organ was removed at a Post mort. held by Dr. McClenman U.S.N., and to whom I was indebted for an opportunity of examining the specimen. The stomach was about four inches long, and about two, and a half wide. The entrance of the oesophagus was almost entirely obliterated; the walls of the stomach throughout varied from a quarter to a half an inch in thickness & the cavity (of the) was

diminished to a space very little larger than an Egg, the mucous membrane was rugous and corrugated —

When I Examined the walls of the stomach microscopically, I found them to be composed almost entirely of fibrous tissue, and granular matter (see plate 2 fig 5). The proper structure appears to have been entirely displaced — This was a case of Extreme interest —

Case. P. E. R. a man of about 45 years of age, has had a swelling on the Buttock for 15 years, soft, & Elastic in its feel. removed by Dr Mitter at Jeff. Clinic 1871 Oct 15. — showed microscopically fat vesicles, and yellow fibrous tissue of a very beautiful character — see plate 2 fig 6. — wound healed rapidly

Case. Joseph Crist. Æt. 56. Presented himself at Jeff. Med. Coll. Clinic with a condylomatous Tumor. Removed by D. Miller. Microscop.ᵗ Examind, showed simple white fibrous structure, so simple that I have given no Plate. 1850. Oct. 26th.

Case. Elizabeth Quinn. Æt. 2½ years. Small, hard, fibrous tumor removed by Dr M. at J.C. Clinic. White fibrous tissue. Nov. 23. 1850. No Plate. This tumor was not congenital.

Case. Tumor of Neck, removed by Dr Pancoast. Nov. 30th 1850. Yellow fibrous tissue, similar to that represented at Plate II, figs. 1 & 2. Tumor brought to me by Mr. Ch. Neff.

Case. — E. S. W., a student of medicine has had for several years a bitter tumor on the left side of the chest. Dr. Mütter removed it 1851 Nov. 9. Proved to be a fibro-plastic growth. I should say it was beginning to enlarge, and to be a little painful. (This tumor was Exd by Dr. S.W.M. & Mr. S. da C.) I found in it (plate 3 fig 1) fibrous tissue, & small non-nucleated, oval, faint cells about the 4350th of an inch in diameter also fat vesicles, epithelial scales, and some filaments of nerves — These small oval faint cells, almost granules, will be found to be present in most growths involving the skin.

"

Case — X. Y. Z. An "Erectile tumor of the face" Has existed for some months, removed at the Jeff. Med. Coll. Clinic on Nov. 12th 1851. by Dr. Mütter (Also Exd by Dr. S.W.M & Mr. S. da C) On microscopic Examin. I found the fibro-plastic

cell as described by Lebert in perfection (See plate 3. figs 2 & 3) at (a) we have the long caudate spindle shape plastic cell, with a distinct nucleus, about the 1/400th pt. of an inch in diam.; numerous shapes of these cells are to be seen in fig. 2 – At (b) I have represented the oval, granular cell, non-nucleated described in the preceding case. – At fig 3. I have drawn the fibro-plas. and oval cells more highly magnified, showing however the same peculiarities. Some of the fibro-plas. cells even show nucleoli.

Case. 1871 Nov. 19. Mr. J. C. Morris presented me with a section of tumor, hanging pendulous from the female breast, removed by Dr. Fox at the Penn. Hospital. The history of the case was imperfect. The tumor was not productive of much pain. On Examination I found the appearance

represented at Plate 3. fig 4. - Epith.l scales, fibro-plastic cells, pecular oval cells, and yellow fibrous tissue. The growth was about as large as a walnut.

Case - S.N. presented herself at the Clinic of Jeff. Med. Coll. with a hard tumor of the breast, giving considerable pain - The tumor had existed . The Breast was removed by Dr Mütter Nov. 19th 1857. Microscopically Examined I found fat vesicles, fibrous tissue, colostrum in some quantity (see Plate 3. fig 5. c) and a considerable proportion of glandular matter, these cells are seen at (d), also oily globules free. The destruction did not seem in this case to have gone on to nearly such an extent as I have often seen it - This is shown by the presence of such a proportion of gland cells - The wound healed well -

Case A. Y. Z. aet. presented himself at the Clinic of Jeff. Med. College complaining of a hard lump, immediately at the symphysis of the chin. This tumor had been some months in forming. The growth was removed by Dr. T. D. Mütter Nov. 22 1851. Microscopically examined it presented the appearance, seen at Plate 4 fig. 1 & 2 — Beautiful cysts of yellow fibrous tissue, (a) some apparently empty & others enclosing oval cells, non, nucleated but dotted, such as are hereafter described, at (d & e) are seen the fibroplastic cells. at c. I have shown Epidermic cells, with single and double nuclei — at fig 2 a is seen a large Epidermic scale, about 1/500th part of an inch in diameter, also the fibro-plastic cells (b). these fibroplastic cells, are about the 1/2500 of an ~~in~~ inch in diameter, and are very long, comparatively — It is worthy of remark, that this patient, had had a tumor of lip, (not examined) removed previously. (Dr. S. W. M. & Mr. J. da C. Exd this T. & took pronounced it fibro-plastic)

Case. 1871 Dec: 10th I rec^d through the kindness of Mr. J. C. Morris a section of mammary tumor removed at hospital – of the history I know nothing. The character of the growth was fibro-plastic (See plate IV. fig 3) at (a) I have shown a mother cell, with young or daughter cells in the interior. This cell was about the 1/300th pt. of an inch in length. at b we have fibro-plastic cells, at (c) fibrous tissue, at (d) the epidermic scale, at (e) one of the comp^d granular cells described by Bennett, & which we find in all tumors, seeming to be a degeneration (if there is such a thing) of other cells, – at (f) free oil globules.

"

Case – 1870 Dec: 14 – I rec^d from Dr. Pancoast through Mr. C. Neff, a tuberc.^m dolorosum of the Ant.^r Tibial nerve. I exp^d it with Dr. Keller of this city (see plate 4. fig^s 4. (1.) this plate is taken from a drawing of Dr. Keller.) at (a) we see the nerve fibres with the white cylinder of Schwann, at b, & c are to be discovered peculiar cells, particularly

~~Caudat~~ caudated, or rather elongated oval, non, nucleated but dotted - These cells were faint, and indistinct, but still with care they could be discerned - This is one form of neuroma - viz a deposit of new & abnormal cells in the interstices of the nerve fibres - I here cannot do better than to group another

Case, On Oct 8th 1871 a girl at 20 presented herself at clinic, with a hard, painful lump on the right posterior supra-scapular space, This tumor had existed for a year, but only during the last 4 months had it occasioned much pain - It was removed by Dr Pancoast, On microscopic Examn it proved to be merely an hypertrophy of the intersting neurilemma (see plate IV. fig 4. ii) merely fibrous tissue could be seen

I have now given the two forms of true neuromatous tumors - The subcutaneous

painful tumor, is a believe only a fibrous tumor pressing upon the filaments of a nerve, I have not however had an opportunity of examining such a specimen.

Case of Cicatrix. At Plate IV fig 5 & 6 I have shown the appearance of a cicatrix removed by Dr. Mütter from the hand on Nov. 8. 1851 at clinic of Jeff. Med. college. At fig 5 (a) is shown the yellow fibrous tissue of which the cicatrix was principally composed, at (b) fat or globules, and at (c) a vague cept with fibrous walls. At fig 6. (a) is fibrous tissue, (b) a capillary vessel, with a diagonal series of trabeculae. What these are I do not know, (c) we here have the nerve tissue, with the white cylinder of Schwann. This cicatrix was quite a large one, and was taken from the hand, the result of a burn. All cicatrices present similar appearances.

Case. At Plate 5 is represented the appearance presented by a cancer of cheek in Samuel Allen Ætat 58, who presented himself at the clinic of Jeff. Med. College – The early history I do not know, but at the time of operation (Oct. 27. 1850), the tumor was a red, fungous, ulcerated mass extending backwards from the angle of the mouth – The mass was removed by Dr. Pancoast. When I examined it, I found the appearance presented at Pl. V figs. 1. 4. & 6. (a) being cancer cells of every size from 1/1000 to 1/3000th part of an inch in diameter, (b) represents the ordinary Epidermic or Epithelial cells, and it has always seemed to me, that these cells, possessed much larger nuclei, when occurring in diseased tissue, than otherwise. At (c) we have fibrous tissue, at (d) the compound granular cells, spoken of heretofore – At (m) fig. 6, we have the mother cells, enclosing young cells, some very full, others as we see enclosing only 5 or 6. – This tumor

returned subsequent to operation, and was again removed on Decr 11th 1830, less than two months after the first operation, I again examd the mass, & found it presenting the same appearance as previously & which I have figured at figs. 2. 3. & 5. pl. V. The wound healed & the patient returned home, but in 6 months died – no post mort. Examn. This was a very marked case of true cancer.

"

Case. 1830 Decr 21. Received from Mr Camac a breast removed by Dr Pancoast in private practice from a lady near Mt Holly. N. J. – Upon examining it in connection with Dr Keller, we found such cells as are represented at plate VI. fig. (b) true cancer cells (1/2000th to 1/4000th of inch in diam.), and (a) peculiar cells, half formed, without nuclei, but dotted. Dr Keller considered these as free nuclei, in a stage of development. By the addition of

Acetic acid, the granules disappeared, & a nucleus was brought into view, which was always adherent to the wall of the cell, fig 2. perhaps instead of the term nucleus, I should say nucleolus. These cells or free nuclei were about the 1/3000th part of an inch in diameter. Throughout the substance of the whole tumor were found small thick cysts filled with oily contents. cysts of fibrous tissue were also to be seen filled with cancer cells from the 1/1500th to 1/2500th of inch in size. a good deal of fibrous structure was present (see fig 3) mother cells, compd granular cells; and also colostrum (in small quantities) could be found. - refer to Plate 6 figs 1-6. for full drawings.

Case. J. B. Hendricks ætat 26. Brought to the Clinic of Dr. C. Oct 12th 1850 with a tumor on the scalp as big as an orange. - Has had this tumor for some months - removed by Dr -

Mitter – On Examination I found cells
as I have drawn at Plate VII fig 1 & 2
Cancer cells, Fibrous tissue and
Epidermic scales – This tumor has
twice come back, & has removed by
Chloride of Zinc – It has now (Jan. 1852)
returned again – The Patient is under Dr Horner's care.

Case – At Plate VII figs 3 and 4
I have drawn from a cancer on
the parotid gland. The specimen was
obtained from a post-mortem made
by Drs Keller & Rammsville & Parrish.
Fig. 3. cancer cells, & Epidermic
scales – Fig 4. same, also pharmacystin – I do not know the
history of the case. – Oct. 18th 1857.

Lavinia Hampton, 5th St. near Federal
Æt 8. presented herself at clinic of Dr. C
with an Epulis of left side superior maxillar. On
the 20th Nov 1850. The tumor had been some months
growing (I think 8 or 9), at first of a white appear-
ance, during the 3 mos. prior to removal it
became of a purple hue. Removed by Dr. Miller
with a large portion of the superior maxillar bone.
Upon examining the tissue with the microscope, I
found the arrangement as shown in Plate VII
figs 5. – (M) mother cells, with daughter cells. (b.)
Epithelial cells. and (a) perhaps cancer cells.
I am doubtful, whether this tumor is really
a cancer or not, its history is not cancerous.
It may be fibro-plastic, I think it is, although
the fact of its having returned during the
last 3 months (Jan. 1. 52) would the former mean-
-ing go against such opinion – Still I am
not able to pronounce, without further
observation –

Case. 1890 Dec. 21. Recd from Dr Keller. Specimens of diseased tissue removed ~~from~~ at a post mort. Exam. of a patient of Dr K. & Dr Pepper's. of the history of case I know nothing — at Plate VIII. fig 1 we have shown ~~at a~~ the appearance of a hard (gritty) crunching mass removed from the anterior mediastinum — at (a) the peculiar cells or pea nuclei described before. At (b) we have true ordinary cancer cells — At fig. 2, we have the appearance of peculiar cells when acted upon by acetic acid in the same manner as described at page in case of Breast. At fig 3. I have drawn the appearance of mass in great pectoral muscle. (a) Muscular fibre altered in character — (b) cells as above — (c) fibrous tissue. Fig. 4 is a mass of a similar character taken from the kidney of same patient, showing fibrous cysts (a) filled with cells of cancer, and (b) true ordinary

cancer cells. At fig. 5 we have the same acted upon by acetic acid as seen before — Fig. 6 — (a) same peculiar cells, (c) uriniferous ducts surrounded by cells. — A. same cells more highly magnified.

Case. Specimen presented to me by Dr. Pettigrew. Mrs P. at 46, a widow & the mother of several children has been ill for several years, complaining of vague abdom. pains, feelings of lassitude &c. and all other symptoms characteristic of Uterine disease. During the year previous to her death the last place in March last, the Epigastric pains increased becoming of a lancinating character; general derangement of the primæ viæ took place the stomach sympathized to a remarkable degree with the Uterus, constant vomiting occurred, & the patient finally sank — During all this period discharges of blood similar to the catamenia ~~took place~~ occurred although at irregular intervals — Upon p. m. Exam.

the thoracic organs were found healthy as also were the liver, spleen & kidneys of both sides. The ovaries were enlarged, the fallopian tube of the R. side had ulcerated off from the uterus, while a considerable deposit had taken place in that of the left side. The fundus of the uterus was much enlarged, & the posterior portion softened & infiltrated with a thick viscid fluid, of a dirty brown color which could easily be squeezed out by making pressure with the fingers. The os uteri was open & distended, its margins ragged & ulcerated, the cavity of the uterus was also enlarged, & was filled with a thick fluid, which was the upper portion of the vagina was much ulcerated. Upon squeezing out from the cut fundus uteri, a portion of the fluid it contained, & submitting it to the microscope, I found it to present the appearance shown at Pl. ~~VIII~~ IX. fig. 1. numerous

cells were to be observed varying greatly in their shape & size, some being round, some oval, and others broad and flat, with a smaller tailed extremity; these cells were larger than those occurring in most cases of cancer, except in those of rapid development or in an advanced stage; they measured from the 1/900th to the 1/2000th part of an inch in diameter, and were possessed of the oval nucleus of the 1/3500th part of an inch in length. (See plate IX figs. 1. 2. 3. 4.), the nucleus varied however in proportion to the size of the cell; a number of the cells possessed however in addition a nucleolus, appearing merely as a granule in the interior of the nucleus. These cells all floated as it were in a sea of granular matter. I observed also several pavement cells, see fig IV. Upon examining the more solid parts of the fundus uteri, cysts filled with cancer cells were to be seen, occurring in the fibrous stroma of the uterus, fig. IV. These cysts were about the 1/500th part of an inch in diameter and about the same depth,

and were formed by the interlacement of the fibres of the adjoining white fibrous tissue. The cells filling these aspts could when carefully examined be found to contain nuclei, compared with the other cells, however they were of small size, being only about the 1/2500th pt. of inch in diameter.

This case is reported at length in Med. Exam^r for Decr 1851.

Case. 1851 April 5th Exd a polypus of the nose, which has returned after 4 removals. Found, fibres, and fibro-plastic cells. Also some cells, resembling cancer, but yet I could not make up my mind as to its being positively cancer, I am inclined however to call it so. See plate IX figs. 5 & 6.

Case. 1851 March. 27th Dr Pancoast removed at clinic of Jeff. Med. College, a tumor situated directly over the left parotid gland of a man at about 40. Upon examination I found the tumor to be such as is represented at Plate X. (Figs 1-2) at Fig 1. are seen fibrous cysts filled with the cancer cells, these cysts being about 1/100th of an inch in diam. cancer cells also of various sizes are to be seen. at fig 2 we the appearance of the fluid squeezed from the tumor. Of the history of this case I know nothing, neither do I of the result of the operation.

Case. 1851 May 15th received from Dr Collett of Phila. a specimen of cancer of oesophagus. The cardiac orifice of the stomach was almost entirely obliterated, the walls of the cardiac end of the stomach were thickened, & hardened, & the oesophagus itself for the space of 3 inches above the stomach, was very much thickened, all the coats participating alike in the lesion. I examined this

specimen most carefully (see plate X. fig 3 & 4.) at fig. 3 we have fibrous tissue, and cancer cells, also crystals of chloride of sodium – at fig 4, Epithl cells, cancer cells, and fibrous tissue highly magnified – The history of this case was the same as that of all those cases of gastric cancer – the patient sank through exhaustion.

Case 1877 Augt 22nd I recd for Examn from Dr Pallisser a portion of the Pancreas removed at antiseptic Exam. for the father of Dr Pilkington, who had suffered vague abdominal symptoms for some months. The mass was very much decomposed owing to the heat of the weather, but yet I feel satisfied that ~~the~~ I was able to make out distinctly, what had been cancer cells, see plate X. fig 5 & 6. – The mass was necessary somewhat indistinct, in fact being in an advanced stage of decomposition.

Cancer of the Pancreas are comparatively rare, or at least few have been reported.

Case. — 25th June 1871 recd from Dr Logan of this city, specimens taken from an arm amputated at the shoulder joint, by him, the day previously — Cancer supposed to be the disease. — The History of the case, was I think that the patient had recd an injury on the arm from a fall, & that gradually a tumor developed itself about the middle of the biceps muscle, — Upon removing the integuments, it was found that a large deposit of a softish matter of whitish color had taken place, not only External to the Bone, but also in its interior, distending the Bone to a mere shell — This deposit was infiltrated under the muscles, & bones, & between them in every direction — Upon Examination I found the appearances depicted at plate XI figs. 1 & 2 — large cells, about 1/300th of inch in diameter — facil, yet distinct, dotted, and most nucleated, but not all — at fig 3 we have the disintegrated muscular fibre, & also the same cells — at fig 4, we have those cells, now nucleated, & small

This case I would consider one of the colloid class.

in size, about the 1/2000th of inch in diam. These cells were found in the interior of the blood clot, my attention was drawn to this point by Dr Ellerton Wallace, the supposition them to be the nucleus of the larger cells, developed in the clot, (as in the bycoma sanguinis, exactly at a certain period in the clot) as a blastema — I am inclined to adopt this opinion, although I have never detected cells in clots in any other case than this — The wound ~~the the~~ healed well, but the patient died in August following the operation, Upon post-mortem Examn almost all the glands of the body were found enlarged, particularly those in the ~~the~~ abdomen & cavity. The deposit (although I had not an opportunity of Examining it) was of precisely the same character as that described above — This case is one of great interest. It speaks volumes with regard to the propriety of operations for removal of certain cancers —

Case 1850 Nov. 18th Exd. with Dr. Keller a cancer of breast removed by Dr. Pancoast from a lady in private practice. Of the history I know nothing.
At Pl. XI. fig 5, I have drawn at (a). gland cells. at (b) cancer cells of all sizes. At fig 6. (a) fat vesicles. (b) fibrous cystic filled with cell. c. Cancer cells.

Case. Jno. Vanderveer. at. 60. On 1857 Feby. 1. Dr. Pancoast removed at Clinic a portion of his lip. Mr. Da Costa Examined, and pronounced it true cancer. On Mch. 19th he again presented himself at the clinic. the submax. of left side having become involved, this was removed by Dr. Pancoast. I found on Examn. gland cells. Plate XII (b), fig 1. cancer cells, &c. comp. granr. corpuscles &c. – true cancer it will be seen. I lost sight of the case till Dec. 1857. I then found he had died in Nov. 1857, the Tumor having returned in the neck. The patient died under the care of Dr. Thomas. In a pathol. recd. of this case, see Mr. Da Costa's thesis.

Case. Henry Clifton. æt. 13. - Had had for a year a tumor involving all the glds. of Head, upper & lower jaw. threatening suffocation. This did take place - I made the post. mort. Examn. Nov. 27. 1850 & found that the right upper & lower maxillary bones, the glands of the neck, the parotid, submaxillary, & thyroid glands were all involved - Upon microscopical examination, I found such cells as I have drawn at plate XII. figs. 2. 3. & 4 - at fig 2 large epithelial cells from mouth (a) & Cancer cells (b). at fig 3. Cancer cells, at globules &c. at fig 4. the same magnified 450 diameters. This was a most marked case of Cancer.

Case. 1851 June 21. Received from Dr Hewson, a section of breast removed by Dr Peace at hospital - I know nothing of the history of case I know nothing. Upon Examn I found what I have depicted at Pl. XII fig 5. & 6 Fig 5 (b) gland cells, (c) cancer cells - Fig 6. same more highly

magnified, & (B) lymphatic - (C) gland cells.

" "

Case 1871 Feb 9 recd from Dr Pancoast a breast for examination, removed by him in private practice. I do not know the history of the case. Upon studying the case it was discovered to be Epithelial in its character, a very rare form of breast disease. (See Plate XIII fig 1.) a. fat cells. (b). Epithelial cells. (c) Crystals of Cholesterine.

Case. 1871 June. recd from Dr. Garrach a tumor
twenty what is generally called.

Case. Mr. Elliott, has had a slight tumor on his tongue for many years, within the last year it has begun to enlarge, Dr. Mitt has removed it many times, every day or two, at fig 3. Plate XIII we have the appearance of the dried, the most superficial cells, at fig 4, the fresh cells. Simple Epithelium

Case. 1851 Sept 13, at hospital Dr. Foy ~~Dr.~~ amputated the glans penis of a man about 44. The tumor was as large as an egg. I ~~got~~ obtained merely a small portion of the external surface, It presented nothing but Epithelial cells and granular matter. From what I saw I am disposed to believe that the tumor was a mere hypertrophy of Epithelium, and not a cancer. I believe Ricord has treated such tumors by paring them down.

Case. 1871 Aug. 28th Recd from Dr Vancourt through Mr Cleff. An Epithelial sac from abdomen. A simple cyst, lined with Epithl cells, & filled up with cells of the same kind, & new see plate XIIIj fig 6. (b) crystals of cholesterin A. Epithel. cells form membrane of cyst. Vesicular.

" "

Case. 1870 Nov. 6th Dr Miller removed at clinic a patient of Epithelial tumor of tongue precisely similar to that of Mr Elliott's tongue recorded on Page

The same drawing will serve for both tumors. Tongue see Plate XIIIj. Figs 3 & 4.

" "

Case H. Y. L. æt 65. - presented himself at Clinic of Jeff. Med. College, with a large red, vascular tumor on the left lower Eyelid, the tumor was increasing rapidly the patient (a farmer) stated that he had had a tumor of the lip removed some months since. The tumor on Eyelid has removed by Dr. Pancoast. - In drawing see plate XIV. figs 1. 2. 3. - Fig 1 shows Cancer cells in abundance, Cancer & Epithel. cells. (Both fig. 1. & 2, represent nearly the fluid of tumor). At fig 3 we have the hair pattern of the mass. showing fibrous tissue and the same cells we have seen above -

I believe, indeed I am sure, that this tumor is cancerous, but by other observers some doubt seems to be entertained as to the true character -

Case Susan ——. a negro woman. aet 70.
A patient of Dr. Coates presented herself at Chi-
of Gen. C. with a tumor of R. Breast, which had
Existed for several months. pain sharp and lancinating
the Breast was removed by Dr. Pancoast — the
tissue appeared dense and hard. I Examined the
Specimen most carefully in connection with Dr. Keller
& Ad. Hewson — The cells I found there shown at
Plate XIV — fig 4. & 5 at (a) small cells' less nucleated
but granular, about 1/2000th of inch in diameter — they were not
Epithelial, nor glandular, nor were they strictly
granular, for tubercle, — I have not therefore
been able to come to any conclusion. Dr.
Keller believes it to be a Species of Hyaline
Cancer — This tumor is interesting inas-
much as there are no positive cases
of Cancer on record in the negro —
The Drawings are very Exact.

Case 1877 Oct. 15. Mr. J. C. Morris brought me a section of breast removed by Dr. Gibson at University of Penna clinic — No history afforded me — The tumor proved cancerous — See plate XIV. fig. 6. fibrous tissue, cells, nt globules &c. &c

" — "

Case. Miss G. æt 21. Had had for some months a small tumor, a wart a large mole on the left side of face. This tumor every a disposition to enlarge and to ulcerate, it was removed by Dr. Mutter Oct. 28th 1877. Merely Epidermic — See plate XV. fig 1. &c the see Dry & fresh Epithelial scales

" "

Case. Nate N. æt 18. presented herself at Clinic of Dr. O. with what appeared to be an Enchondromatous tumor on the great toe directly under the nail, This tumor was

Removed, and the Examn proved to be merely an unusually increased secretion of Epith. cells under the root of the nail of the toe, the hair composing the mass gave it an almost cartilaginous hardness — See plate XV. fig. 2.

Elias Ireland. Æt 55. Came to clinic of Dr. C with an Enormous tumor of lower lip, apparently Epithelial — Had existed for 2 years, but never caused much pain till lately. The whole lower lip was involved — For figure see plate XV fig 3 & 4 — at (a) fig 3 we have a hair shown, (b) mucus, (c) Epithelial cells, — (d) — cells such as are found in most cases of Epithelial growth, before described — at fig 4 we have (a) these same cells, (b) cells that I believe to be cancer, (c) fibrous tissue — My friend Mr. da Costa considers this tumor to be merely Epithelial, I cannot quite agree with

him. he however did not see any cells such as I have drawn at (b) fig 4. — I will not positively state that this tumor is cancerous although I think that it probably is — the history I would say is certainly not cancerous —

"

Case. X. Y. Z. ætat 40, a woman had had for some 6 months a tumor of jaw — apparently Epithelial — removed by Dr Pancoast — Octr 17th 1857. at Clinic S. M. C. — The tumor Extended far back behind the half arches of palate & down into throat. — See plate XV fig 5 a. mucous. (b) Epithelial scales, c. peculiar small non-nucleated cells. This tumor is only an Epithelial growth

"

Case 1857 Nov. 8. At Clinic S. M. C. Dr Miller removed a mole from the forehead. merely Epidermic — the Mult-

of a hair is so beautifully shown that I have copied it. See plate XV fig 6.

Case. 1871 Sept. 13. at hospital Dr Fox removed a cancer of lip of 2 years standing from old man of 60 years. On Examn I found the cancer cells, Epithelium & fibres tissue see plate XVI fig 4. This case is more particularly detailed by Mr de Costa in his thesis.

Case. E.V.B. at 60 years presented himself at Clinic of Dr. C complaining of Hemorrhoids. He stated that he lost large quantities of blood, & was desirous of having the tumor removed. This was accordingly done by Dr Vancourt in Sept. 13th 1871 of Dr. C's Clinic. The tumor was about the size of a small orange, soft to the touch, crushing down

under the fingers, and very vascular. It had occupied only 4 weeks in attaining its present size. The mucous membrane of the Rectum, at the point at which the pedicle of the tumor was attached, felt hard, & scirrhous like in its character. Judging from external appearances the tumor was apparently malignant. And its portable return was stated to the class. Upon squeezing out the fluid of the tumor & Examining it I found it to contain many cancer cells, (See plate XVI fig 3. a) in the more solid part of the tumor, some although not very much fibrous tissue could be found. This case is reported in full in Med. Nov. Wm of Medical Exam.

Case (I have mislaid my notes of this case & have been obliged to quote from memory.)

F. Y. L. at about 30 presented himself at Clinic of Dr M. C. with a lupus, involving the eye & ~~body~~ cancerous tissues. Removed in Feby. 1857 (Sketch). The mass presented the appearance I have given at Plate XIV Fig. 1. (A) a portion of the optic nerve. (B) fibrous tissue & cancer cells. (C) cancer cells.

At fig. 2 we see compound granular cells, cancer cells, free nuclei, granules &c. The deposit had also taken place in the retina of the Eye &c.

I regret that having mislaid my notes, I am not able to furnish a fuller account of that case.

— " —

Case. Frances Carpenter. Æt. 30. Has had a cyst on the R. loin for 13 years - removed by Dr. Yo. Mitter Nov. 6th 1870. Upon Examination found to be a simple Epithl cyst. (See plate XVI figs V & 6

Fig 5. (a) Crystals of cholesterine. (b) Old cells in the centre of mass. c. fresh tissue cells. fig 6. Crystals of cholesterine

---

Case. 1871 June 21 Dr. Pancoast at clinic removed from a patient about 70 years old a tumor of the lower maxillary bone, & the right side. - The tumor had been some months in forming & involved not only the bone, but also the circumjacent tissues. Upon examining the specimen I found the appearance such as is represented at plate XVII figs 5, 6 & 4. - Cancer cells. Epithelial cells & fibrous tissue as we have seen before and also some peculiar Epith. cell for wh. see figures

Case. At Plate XVII figs 1–4 are seen the cells found in a tumor involving the bone of the lower jaw [This specimen was left anonymously at my door & I do not know the history] At fig 1. We have bone healthy, as it appeared when dried; also some cells floating free. At fig 2. Cancer cells of large size singly & doubly nucleated. Figs 3 & 4 Epith.l cells, fat vesicles fibrous tissue &c. This specimen is one of what might be called true osteo-sarcoma, or better osteo-carcinoma, i.e. cancer involving bone. This subject of cancer in bone has been at various periods much mystified, but it seems to me to be simple enough – considered, as cancer would be any tumor

1850 Dec – Case. D. T. D. Mütter removed a polypus nasi at clinic of J. M. C. It had been removed, & had returned several times. a good deal of ulceration had taken place in the nasal cavities. See plate XVIII figs 1 & 2 fig 1 showing fibrous tissue cysts & cells, – fig 2 showing the same more highly magnified & am inclined to believe this tumor to have been cancerous, but I will not be positive –

Case. 1850 Oct – 23 D. at Clinic Dr. Mütter removed from Peter Dunbar, Ætat 42. an Epithelial Tumor of the lip. See plate XVIII fig 3 – Epithelial cells. Fat – small oval cells, which seem to be peculiar to Epithelial growths, & some cysts mould & cells – say – I think, that to say the least, this tumor is suspicious –

Case. 1857 Oct. 27th Received from Dr. Schively resid. Physn. at Blockley almshouse some fluid from an ulcer on flank penis. I examined it & found it cancerous. See plate XVIII fig 4. This was also Exd by Mr. da Costa & Dr. S. W. Mitchell & both agree with me in pronouncing the tumor cancerous.

Case. In spring of 1857 (April I believe) Dr. Mütter removed from the groin of a patient (Mr. L.) a gouty concretion, which been many years in depositing. I examined the tumor microscopically & my friend Mr. da Costa tested it chemically. The results of the Examination will be seen at plate XIX figs 1, 2 & 3.

Case. Thomas Andrews Æt 30., Barber.
In Feby 1870 he perceived a swelling in right testicle & in the April following he experienced considerable pain of an aching character. This continued all summer. At the commencement this tumor was soft, but in April & May it became hard. On Oct. 26. 1870 the right testicle was removed by Dr Mütter at Clinic J.M.C. The patient being of a hemorrhagic diathesis great hemorrhage followed. During the spring & summer of 1871 the deposit returned in the left testicle, which was removed Oct. 11. 1871 by Dr D. Matter at J.M.C. Clinic. I examined both testes. The one removed in 1870 I injected with Ether & Vermillion. The non vascularity of tubercle was well shown, proving it a deposit & not a growth. The preparation is in the museum of Dr Mütter. At Plate XX figs 1. & 2

I have drawn the microscopical appearance of the deposit. Fig 1. is that of the right testicle removed in 1850. At fig 2, the deposit in left testicle is shown. It will be observed they are precisely similar. Small cells about 1/2500th of inch in diameter, for the most part non-nucleated, dotted & granular in appearance, floating among an immense number of granules.

Case 1852 January 7th. Made a Post. mort. of a Negro woman aet 70. Found pleural clots on both sides of heart, extending into all the vessels, Left Lung spotted over with miliary tubercles &c. &c. Upon examining these spots of tubercle, I found the appearance shown at the XX fig 3. Cells of tubercle & granular matter. This tubercle being in an incipient stage, many a most of the cells were nucleated, differing in that respect from the preceding case — . —

1857 Nov. 19th. J.H. at 19 – a patient of Dr Moore-house, has had a tumor of the size of a Shilling on the skin – Has had the tumor 6 weeks – removed by Dr Mütter – I found it out, Epithel – my friend da Costa pronounced it cancer most probably – On Dec. 15 the tumor returned in the old scar – removed by Dr M. at office. Examined it – again but not able to make up my mind – see plate 3. fig 6. Epith. cells, fibrous tissue, & small oval cells. The full description of this case, see Mr da Costa's thesis.

Case. 1850 Nov. 6th Stephen Lee at 24 presented himself at the clinic of H. M. O with a tumor of the right breast – The whole mass was removed by Dr Mütter and on Examination, I found it to be lobulated, presented the granules, and

cells of a low order of organization
See plate XX. fig 4

"

Case. 1851 October 15th received from Dr Henson resid. physician at Penn. Hospital, two specimens of intestine, one of the lung and one of the intestines. I do not know the history of the case. See plate XX fig. 5 & 6.

"

Case. 1851 Nov. 21 Rec. from Dr Schively resid. Physician at Blockley Alms house, a portion of a carcinomatous uterus, removed at a P. M. Examination. History of Case unknown. at Plate XXI. fig 1. (a) are seen the cancer cells squeezed from the deposit lying into the ovary. (b) pus. at (c) cancer cells, in the harder portion of the uterus. (d) fibrous tissue. fig 2 (a) cells perhaps cancer

found near the os uteri. (b) - cancer cells. (c) fibrous tissue - (d) Candated cells, 450 D.
The patient was a woman at 42 - Symptoms all those of cancer - Death occurred from Exhaustion - At the autopsy, all was found healthy Except genital organs.

"

Cell. Plate XXI fig 3 - Cells from cancer of rectum, given me by Dr Ad. Henson 1871 Nov 22d. — no History

"

Case 1871. Dec 4th Dr Pancoast removed in consultation with Dr Parrish a tumor of the R breast from Miss Cooper. Aet 35
The tumor had Existed for 3 years 8 mos, & until March was only 1½ inches in diameter, since that period it has Enlarged very much the open fungoid ulcer formed, projecting like a mass as large as a walnut from the side of the nipple - Pain lancinating - axillary glands indurated.

On one side of the nipple, what may be called a fungoid growth had taken place since last March, soft, & cerebriform. This specimen is now in the cabinet of the college of physicians of this city. See plate XXI figs 4, 5 & 6 — fig 4 (a) cancer cells from soft part of tumor — (b) fibrous tissue — (c) peculiar cells (perhaps glandular) — (d) cancer cells — figs 5 & 6 (cancer cells.

Oct 10. 1871 Dec 6th Dr Pancoast removed from a lady Miss G — a tumor involving the mammary gland which had existed for 6 months — Pains lancinating — The axillary glands much involved, & were removed by Dr P.

The axillary glands were also removed. – See plate XXII fig 1 & 2. Upon squeezing out some of the fluid of the tumor & examining it. I found it to present the appearance shown at plate XXII fig 1 (A) – compound granular cell – (b) caman cells. –

In the harder portion of the soft matter we have such cells as are shown at C – At fig 2, the structure of the axillary glands has shown – (a) cells (perhaps) Epithelial – (b). glandular cells. – (c) free oil globules – (d). is the structure of the nipple – (yellow Elastic wavy bands) (e) the fibrous structure of the tumor enclosing cells

Case Mrs Poole - a patient of Dr Morris, of this city some year ago received a blow on the Breast, a few months ago, a tumor became visible, accompanied by lancinating pains. On the 15th Dec - 1857 the tumor was removed by Dr Morris - The cells found, are shown at Plate XXII fig 3 - I believe them to be cancerous, but am not positive. I do not think the tumor will return, that is to say, if any cancers do not return, I should think this was one of them. —

Case 1850 Oct - 12. Henry Portyle æt 71, a Shoemaker, had removed from near the umbilicus, a hard, red mass, apparently malignant. Under the microscope found it to be Epithelial, & not cancer - This tumor had existed for many years - cause the pressure of a last - on the Belly - See Plate XXII fig 4.

Case. A. Eshler aet 35 Student of Med. had removed from his left fibula at the head, & adjoining the tibia an Exostosis as large as a walnut. which had Existed for some years.

Microscopically - the Exostosis was found to contain internally a soft mass, apparently Malignant, but found to be merely fat as fat vesicles, & free oil - Margaric Acid Crystals were also found in abundance

Case. R. Y. L. aet 75. Health good. Hashad for 2 years a tumor on the heel which lately has increased so as to render Motion Extremely painful - Removed by Dr Pancoast Decr 6th 1881 - Found to be a multilocular cyst, filled with Epithelium the locules of the cyst communicating & Extending up between the tendons into

the leg. In this case I refer to the Drawings of case of Frances Carpenter page 101.- The contents were Exactly similar Chrystals of Cholesterine, and Epithelial Cells

" "

To face plate 1.

Fig 1. Fatty tumor of arm. See page 50
a – fat vesicles.
b – Fibrous tissue
c – free oil globules

"

Fig. II. Fatty tumor of neck. See page 51.
a – fat vesicles
b – fat vesicles with crystalline nuclei of margaric acid.

"

Fig 3. Fibro-fatty tumor of breast. See page 52
a. Fibrous structure showing oval nuclei after the addition of acetic acid.
b – fat vesicles, with crystals of margaric acid
c – free oil globules

"

Fig 4. Fatty tumor from face.
See page 57.

"

Fig 5. Fibro-fatty tumor of thumb (congenital)
a. – fibrous tissue (yellow)
b – fat vesicles
c – free oil globules
See page 57

"

Fig 6 Fatty tumor. showing Crystals of margaric acid both on the interior & Exterior surfaces of cell walls.
b – free oil globules
See page 59

Plate 1.

Fig. 1

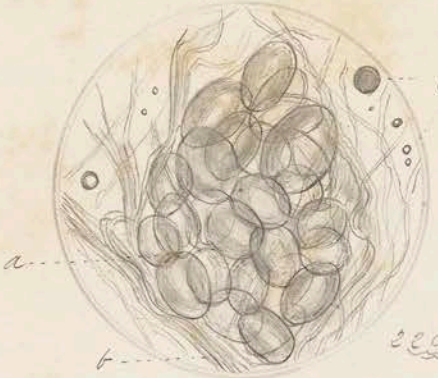

220 D

Fig. 2

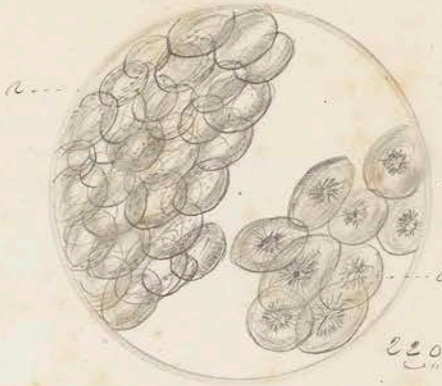

220 D

Fig. 3

220 D

Fig. 4



400 D

Fig. 5

220 D

Fig. 6

220 D

To face pl. 2

Fig. 182 Fibrous tumor of Heel - See page 61 -

Fig. 1. a - fibrous structure
b - one or up, old, Epithelial scales.
c - wavy bands of fibrous tissue

Fig. 2 a. fusiform corpuscles forming fibre.
b - fat cells
c. fusiform corpuscles, magnified more highly, showing nucleus

"

Fig 3 Fibro-fatty Tumor of Breast.
See page 59.

a - Epithelial scales from skin
b - fat vesicles.
c. - free oil globules
d - fibrous tissue

"

Fig 4 Cancroid of Ear. (Wholly fibrous tissue (yellow)
This tumor is always described as cancroid, it is simply a tumor of yellow fibrous tissue, and occurs as in this case in the lobe of the Ear. See page. 62.

"

Fig 5 Fibrous thickening of walls of Stomach
See page 63.

"

Fig 6 Fibrous tumor of Buttock
See page 64.

a - fat vesicles
b - free oil globules
c - fibrous tissue

Plate 2.

Fig 1

Fig 2

Fig 3

Fig 4



Fig 5



Fig 6

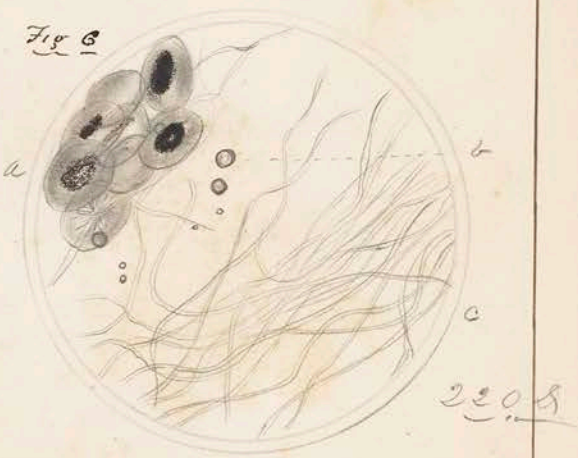

To fig pl. 3

Fig. 1 Fibro plastic tumor from face. See page 66

a — Fibrous structure
b — Peculiar, oval, cells, non nucleated 1/3500th inch in diam.
c — Nerve filament and bundle.
d — Shed Epidermic scales.
e — fat vesicles
f. — Oil globules free

"

Fig. 2 & Fig. 3 Tumor of Face of a fibro-plastic character See page 66.

a — fibro plastic cells.
b — oval cells, of a peculiar character described in text.

"

Fig 4 Fibro-plastic tumor of Breast See page 67

a — Epidermic cells
b — fibro-plastic cells
c — peculiar oval cells
d — fibrous tissue (yellow) —

"

Fig 5 Fibrous tumor of Breast See page 68

a — fat vesicles
b — fibrous tissue
c — colostrum globules, the 1/8000th of an inch in diameter & granular in appearance. tinged brownish in color.
d — gland cells about 1/4000th of inch in diameter
e — free oil globules.

"

Fig 6 Tumor of Chin See page 107

(a.) Epithelial cells.
(b.) fibrous tissue
(c.) Small oval cells.

Plate 3

Fig. 1

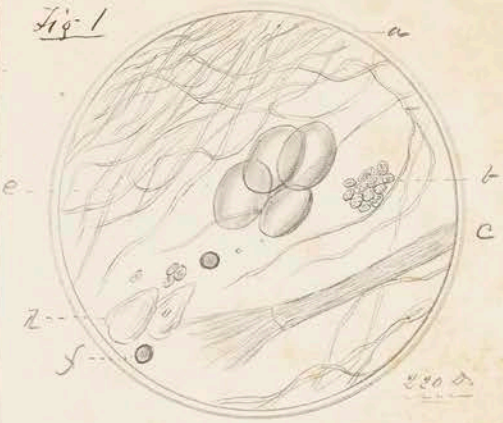

Fig. 2

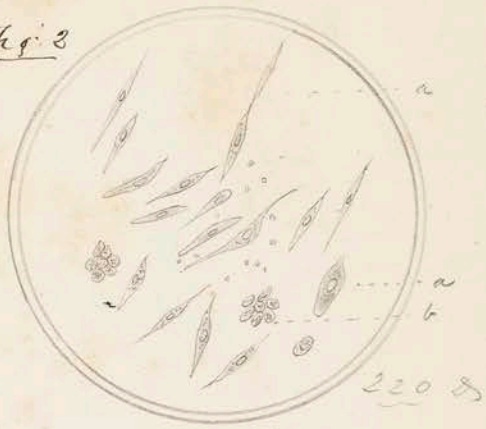

Fig. 3

Fig. 4



Fig. 5

Fig. 6

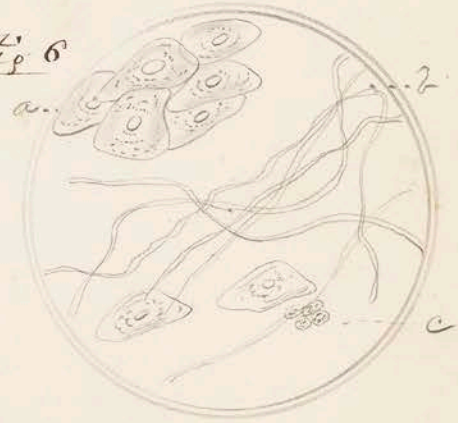

Face Plate IV

Figs. 1 & 2 — Fibro-plastic tumor of Chin See page 69.

Fig. 1
a - fibrous cyst walls
b - peculiar oval cells
c - Epithelial cells
d - fibro-plastic or fusiform cells } with nuclei
e - " "

Fig. 2.
a — Epidermic cell. } showing nuclei
b — fibro-plastic cell.
c — peculiar oval cell.

"

Fig 3 — Fibro-plastic of Breast - See page. 70.

a - mother-cell -
b. fibro-plastic cells of different shape & size.
c. fibrous tissue in bands.
d. Epidermic cell
e - compd granular cell.

"

Fig 4. — Two cases of Neuroma See page 70

1. a - nerve fibres.
b. peculiar cells between nerve fibres.
c - "

2. (aa) nerve fibres See page 71.
(bb). fibrous tissue (in reality this tissue forming a hypertrophied sheath to nerve.)

"

Fig. 5. & 6 — Cicatrix from hand See page 72

Fig 5 -
a — Yellow fibrous tissue.
b — fee oil globules
c — vague cyst.

Fig 6
a — fibrous tissue
b. — capillary ball of Blood
c — nerve fibres

"

Plate IV

Fig 1

Fig 2

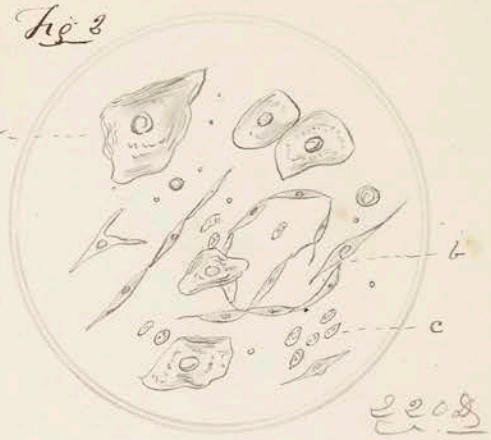

Fig 3

Fig 4

Fig 5

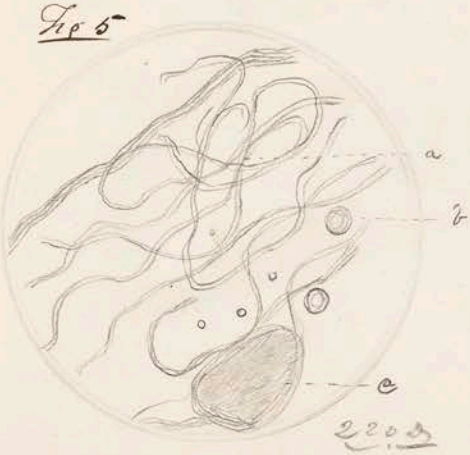

Fig 6

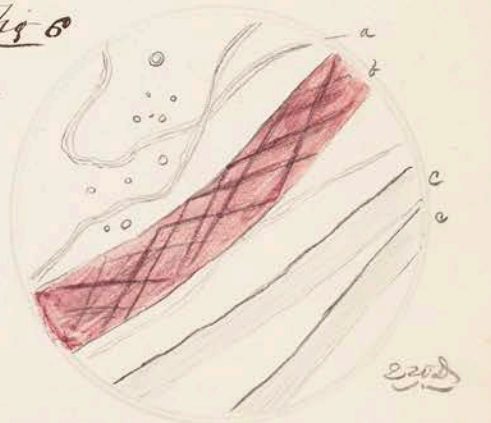

To face pl. V

Cancer of Breast see page 73

Figs. 1 4 & 6 (after 1st operation)

— (a.) cancer cells
(b.) Epidermic & epith. scales.
(c.) fibrous tissue
(d.) compd. granular cell.
(f.) — free oil globules.
(m.) — mother cells, in closing young cells
(n.) Caudated cell.

Fig. 2 3 & 5 (after 2d operation)

Annotation the same as above —

Plate V

Fig 1

Fig 2

Fig 3

Fig 4

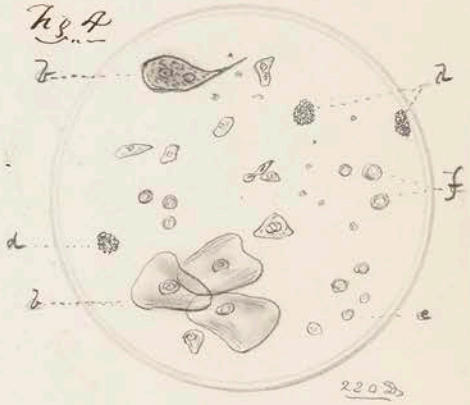

Fig 5

Fig 6

In Tex pt. VI

Fig. 1. – 6. } Tumor of Breast. (Cancer) See page 74

Fig. 1. a – Peculiar cells – see text.
b – Cancer cells

Fig. 2. – Cells represented at Fig. 1 a, are seen after the addition of Acetic acid with an magnified still higher showing the nucleus on the cell wall.

Fig 3. (a.) Compd Granular cell.
(b) – free oil globules
(c.) Blood ~~globules~~ corpuscle.
(d) Colostrum.

Fig 4. Cysts in Breast showing cancer cells.

Fig 5. Fibrous structure, (Cancer cells (a)
(b) parent cell.

Fig. 6. (a) parent cell – 1/500th of inch in diam.
(b) – Simple cancer cell.

Plate VI

Fig. 1

Fig. 2

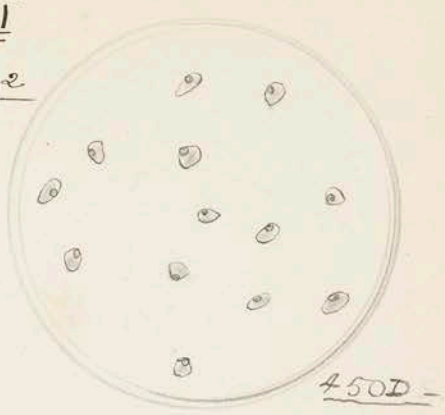

Fig. 3

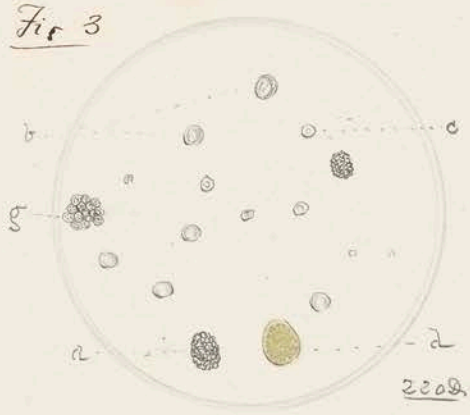

Fig. 4

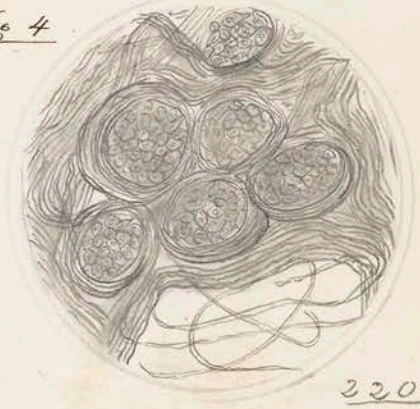

Fig. 5

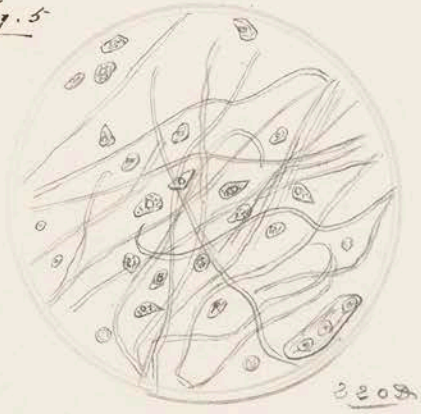

Fig. 6

To face pl. VII

Fig 1 & 2 — Cancer of Head. Dr J. Hardwicke. See page 75
Fig. 1. Cancer cells
" 2 " " & Fibrous tissue.
"

Fig 3 & 4 — Cancer of Parotid. See page. 76
Fig. 3 — cancer cells & Epidermic cells.
" 4 " " " & fibrous tissue.
"

Fig 5 & 6 — Epulis. See page 77. Cancer?
Fig 5. Parent cells (m)
(b). Epithelial cells.

Fig 6. Action of Iodine on cells.

Plate VII.

Fig 1

220 D

Fig 2

220 D

Fig 3

220 D

Fig 4

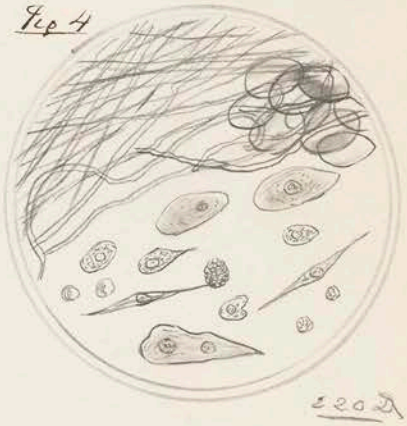

220 D

Fig 5

450 D

Fig 6

220 D

Figs 1–6 – Cancer from Ant^r mediastinum, pectoral muscle, & kidney – see page 78.

Fig. 1. a. Peculiar cells. (see text)
b – Ordinary cancer cells.)

Fig. 2. Same acted on by acetic acide. 450 D.

Fig. 3. Masses from pectoral muscles
a. – muscular fibres.
b – peculiar cells.
c – fibrous tissue.

Fig 4 Fibrous Cyst from kidney.
a – cyst.
b. cells.

Fig 5 Same treated with acetic acide.

Fig 6 – (A) cells surrounding (C) a small uriniferous duct. – (A) same more highly magnified.

Plate VIII

Fig. 1

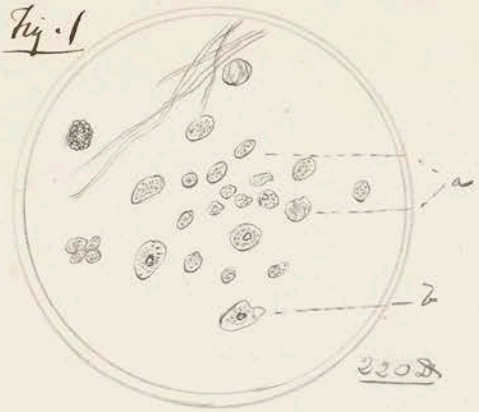

Fig. 2

Fig. 3

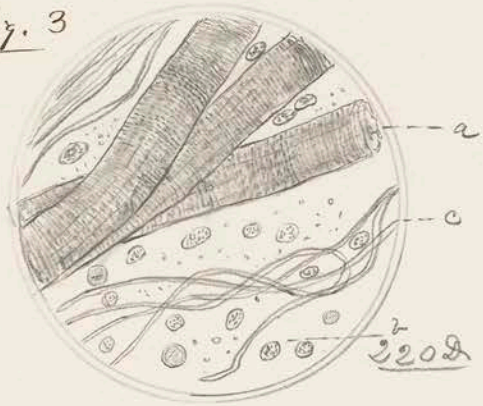

Fig. 4

Fig. 5

Fig. 6

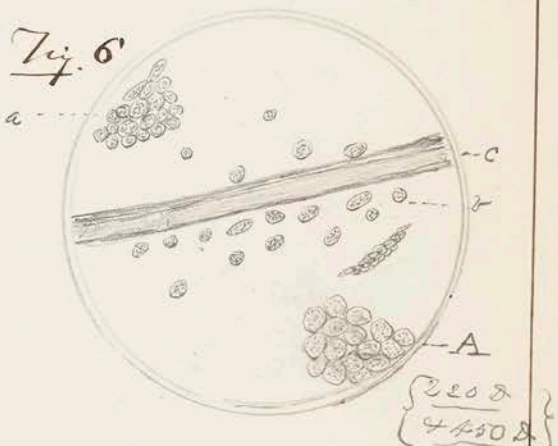

To face plate IX.

Fig. 1 — Cancer cells from tumor of Uterus floating in a sea of granules. } See page 79 — from fluid of fundus uteri }

Fig. 2 — Cancer cells, granules, & fibrous tissue —

Fig 3 — The same (from the harder portion of the fundus.

Fig 4 — Cysts (a) filled with cancer cells.
(b) parent cells.
(c.) compd granular cell }

Fig's 5 & 6 — Polypus of nose. See page 82

Fig 5. Fibres, fibro-plastic cells, & perhaps Cancer cells.

Fig. 6. Fibres, Epithelial cells, & fibro-plastic cells — perhaps also Cancer cells

Plate IX.

Fig. 1

Fig 2

Fig 3

Fig 4

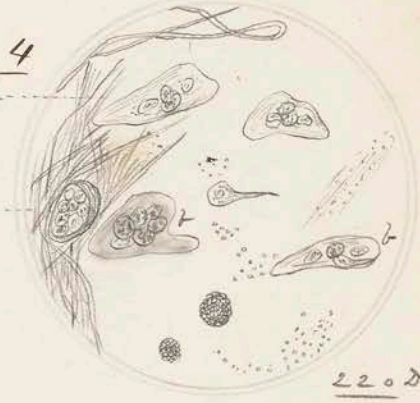

Fig. 5

Fig. 6.

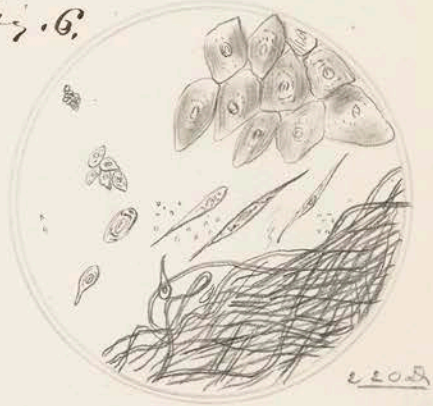

to face p^r 4

Fig. 1. Cancer over Parotid gl^d. See page 83

Shows (a) Capt. filled with cancer cells of 1/2000th of hell diam.
& (b) for cancer cells of about 1/800th to 1/400th " "

Fig. 2 — Cancer cells of same —

No 3 Cancer of Oesophagus — See page 83
(a) Crystals of common salt
(b) Cancer cells of various types
" "

Fig 4. Same. More highly magnified.

Fig. 5 " Cancer of Pancreas — See page 84
& 6 Cells indistinctly shown, owing to decomposition having taken place
"

Plate X

Fig. 1

Fig. 2

Fig. 3

Fig. 4

Fig. 5

Fig. 6

to face pl. XI

Figs 1-4 | Colloid Cancer of arm. See page 85

Fig. 1. - Cells from deposit - from 1/90th to 1/200th pl. of hel & Hamilton

Fig 2 — " — " — " Mag. 450 diameters

Fig 3 Disintegrated muscular fibre. (from Neoplasm) & Cells as above

Fig 4. Peculiar cells found in cell - non - nucleated probably from nucleus - See text -

" "

Fig. 5 Cancer of Breast. See page 87

a. Gland cells. Non nucleated 1/400th inch in d.

b. Cancer cells.

Fig. 6 - (a) fat globules

(b) Cyst. filled with cells.

(c) - cells -

" "

Plate XI

Fig 1

Fig 2

Fig 3

Fig. 4

Fig 5

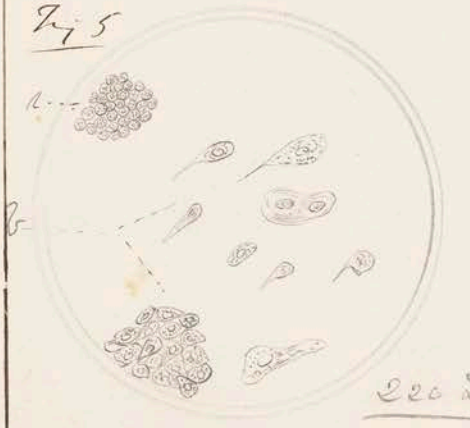

Fig. 6

to face pl. XII

Fig 1 Cancer of Submaxillary Gland, following Cancer of Lip – see page 87.

(a) Cancer cells.
(b) Gland cells.
(c) Compd granular cell
(d) Cancroids cells.
(e) Cyst filled with cells

Figs. 2. 3 & 4 Osteosarcoma – see page 88

Fig. 2. (a.) Epithelial cells, with large nuclei
(b). Cancer cells.

Fig. 3. (a.) Cancer cells
(b). Cancroids cells.
(c) Blood capillaries.
(d) Oil Globules
(e) Cancer cells

Fig 4. (a). Cancer cells
(b.) Oil globules.
(c) Compd granular capsules.
(d) Epithel cells.

Figs 5 & 6 Cancer of Breast. see page 88

Fig 5. (a.) Oil & fat
(b). Gland cells.
(c) – Cancer cells

Fig 6. (a) Lymphatic.
(b) Compd granular cell
(c) Gland cells.
d. Cancer cells

Plate XII

Fig. 1

Fig. 2

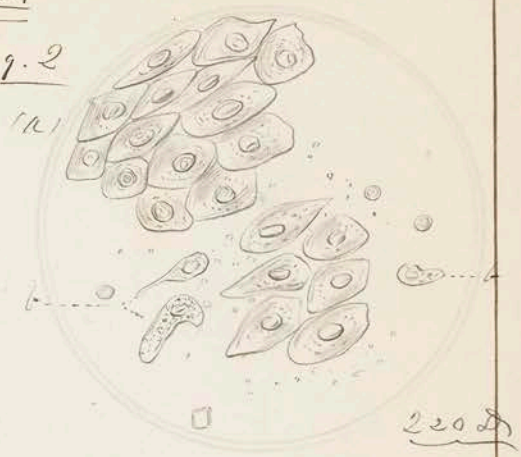

Fig. 3

Fig. 4

Fig. 5

Fig. 6

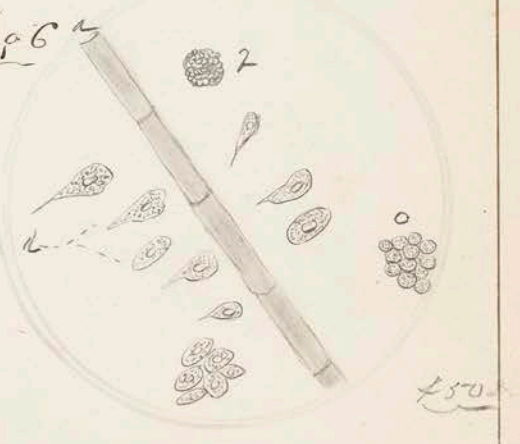

1 face plate XIII

V	Fig 1.	Epithelial tumor of Breast. See page 89 (a) – fat cells (b) – Epithelial cells. (c) – Crystals of cholesterine.
V	Fig 2	Epithelial tumor. Epithelial tumor. See page 90 (from stomach)
	Fig 3.	Cellular tumor. Epithelial of Tongue
& 4	Fig. 3. Dried Epth. Cells.	See page 91
	" 4. Fresh " "	
	Fig 5	Epithelial of Penis (?) See page 91 a – fresh cells b. old "
	Fig 6.	Epithelial ~~tumor~~ cyst. of abdomen. See page 92 a. cells forming lining membrane b – old cells & crystals of Cholesterine

Plate XIII

Fig 1

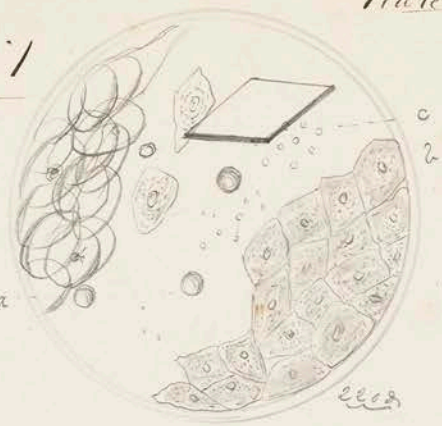

Fig. 2.

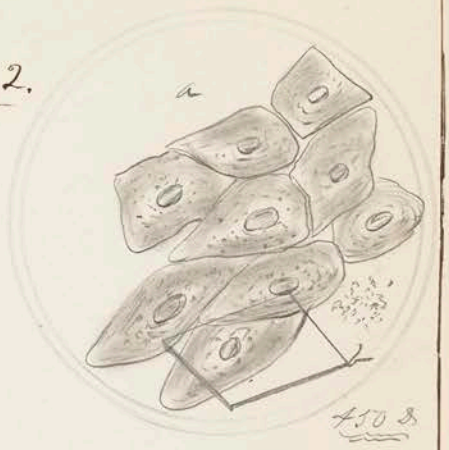

Fig 3

Fig 4

Fig 5

Fig 6

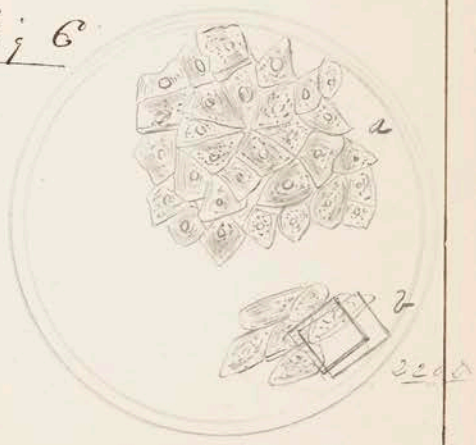

to face Plate XIV

Fig 1. 2 & 3 — Cancer of Eyelid. See page 93

Fig. 1. Cancer cells, Compd granular cells &c

Fig 2 " " " " 4D Diameter

The above two figs represent cells found in the fluid squeezed from the tumor.

Fig 3. Hard portion of same tissue, showing fibrous tissue in addition to the cells.

"

Fig 4. & 5 — Cancer of Breast (?). See page 94.

Fig 4 a. peculiar cells described in text

b. Compd granular cells.

Fig 5 — Fat of the tumor.

"

Fig 6 — Cancer of Breast — See page 95.

Cancer cells, at globules & fibrous tissue.

" "

Plate XIV

Fig 1

Fig 2

Fig 3

Fig 4

Fig 5

Fig 6.

Upper plate XV

Fig 1 . Epith. of Face. } See page 95 –
or rather Epidermis }
"

Fig. 2 . Epithelial of Toe { Apparently Enchondromatous. See page 95.
"

Fig. 3 + 4 Tumor of Lip. (Cancer?) See page 96
Fig. 3. (a). Hair –
b. mucus
c. Epithelial Scales
d. pearl cells see text }
Fig. 4 (a) – do –
(b) Cancer cells (?)
(C) fibrous tissue. See page
"

Fig 5 Epithelial Tumor of Mouth See page 97.
(a) mucus – b. Epith. cells – c. pearl cells.
"

Fig 6 Hair bulb &c. in mole See page 97
"

Plate XV

Fig. 1

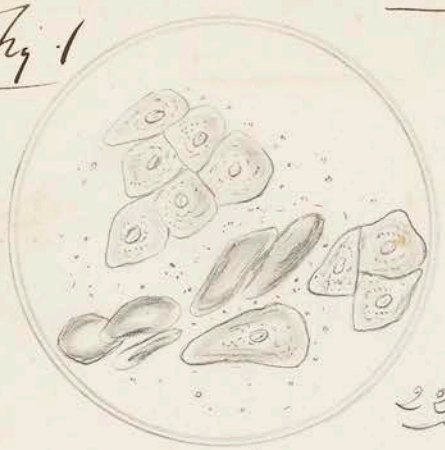

Fig. 2

Fig. 3

Fig 4

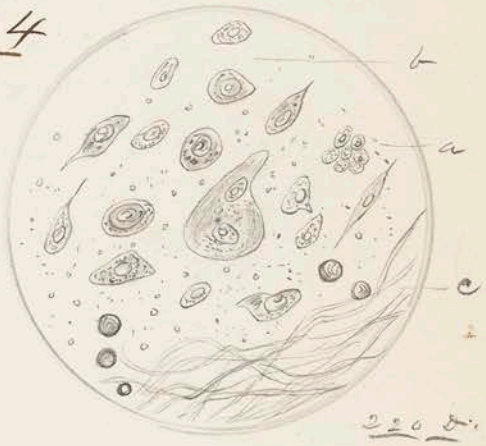

Fig 5

Fig 6

Chart pt. 16

Fig. 1 & 2

Fig. 1. Cancer of Eye & surrounding tissue – See page 100

— (a) filaments of optic nerve,
(b) fibrous tissue of sclerotic & cancer cells
(C) cancer cells.

Fig. 2. Cancer cells, comp.d granule cells, &c. – 450 D.

Fig. 3. Malign.t growth from rectum See page 98

(A) – cancer cells –
(b) – fibrous tissue

Fig. 4 Cancer of lip. See page 98.

Cancer cells. Epithelial cells & fibrous tissue

Fig. 5 & 6

Epithelial Cyst. See page 101

Fig. 5. (a –) Crystals of cholesterine
(b) Old cells
C. Fresh cells

Fig. 6 Crystals of Cholesterine

Plate XVI

Fig. 1

Fig. 2

Fig. 3

Fig. 4

Fig. 5

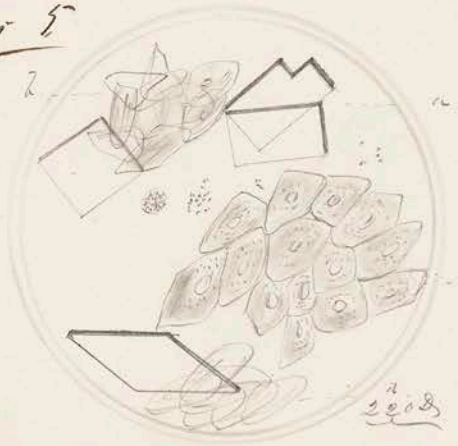

Fig. 6

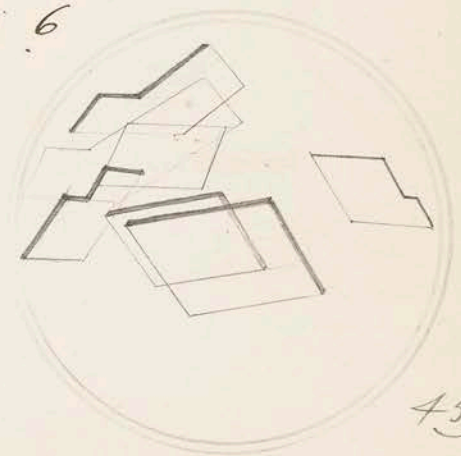

to face plate XVII

Figs 1–4 | Pilé - Carcinoma - See page 102

Fig. 1. Bone when dried. also cells (fresh).

" 2. Cells of Cancer of various kinds.

" 3. Epithel cells, fat, & cancer cells.

" 4 ——— ——— " & fibrous tissue

——— " ——— " ———

Figs. 5 & 6. | From Rima of Lips. See page 101

Epithelial cells. And cancer cells. g.

Fig. 6 Curious candated cells.

g. Carcinoma not?

Plate XVII

Fig. 1

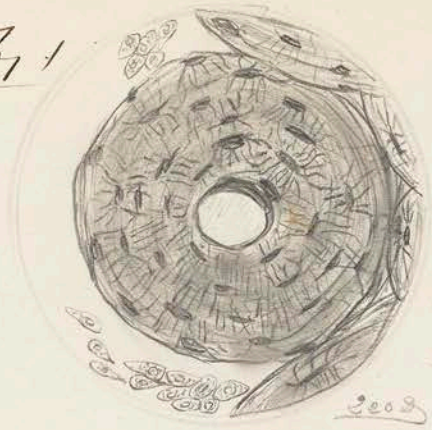

Fig. 2

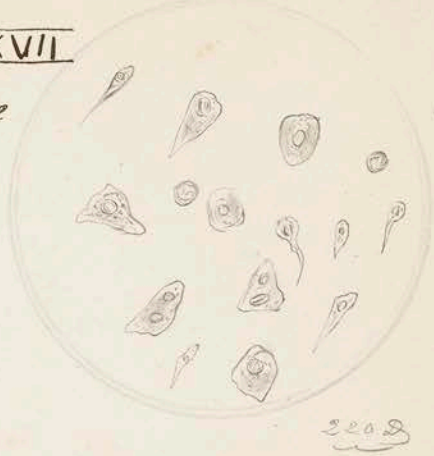

Fig. 3

Fig. 4

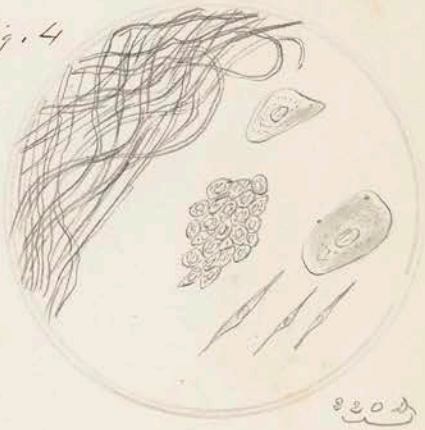

Fig. 5

Fig. 6

To face pl. XVIII

Figs 1 & 2. Malignant Polypus (?) See page 103

Fig. 1 - (a) Cancer cells
(b) Oil globules
(c) Compd granular cells -
fibrous tissue & cyst

Fig. 2
Fibrous tissue, cells, & compd granular cells -

"

Fig. 3 Epithelial Tumor of Lip See page 103
showing Epithelial cells, fat, & cyst in fibrous tissue.

"

Fig 4 Cancer of Penis - See page 104.
Showing Epith. Cells. Cancer cells, compd granular
Capsule, granules &c

"

Plate XVIII

Fig. 1

Fig. 2

Fig. 3

Fig. 4

To face plate XIX

Figs 1, 2 & 3 — Gouty concretion from toe - See page 104

Fig. 1 (a) Most probably a chrystals of double salt of Urate of Soda and magnesia - possibly there are however chrystals of Hippuric acid

(b). The same -

Fig. 2 (a & b) chrystals of Urate of ammonia.

Fig 3. (b) chrystals chloride of Sodium (this is the common form) (a) a rare form of chrystals of Chloride of Sodium.

"

Plate XIX

Fig 1

Fig. 2

Fig 3

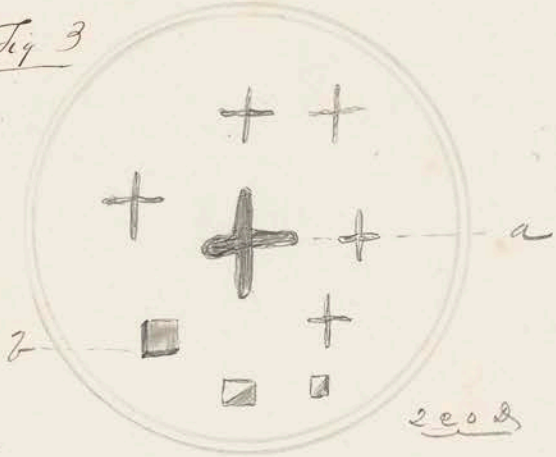

Fig 4

Fig 5

Fig 6

To face plate XX

Figs 1 & 2 } Tubercle of Testis See page 105 –
(a) cells of tubercle for most part non-nucleated – (b) granular matter –

Fig 3 Tubercle of Lung (Miliary) See page 106
(a) cells of tubercle (many nucleated, inasmuch as this deposit had not just commenced) (b –) granular matter –

Fig 4 Tubercle from Breast of Stephen Lee See page 107.

Fig 5 & 6 Tubercle of Lung } " " Intes from Hospital. See page 108.

Plate XX

Fig 1

Fig 2

Fig 3

Fig 4

Fig 5

Fig 6

(be fore plate ~~A.~~ XX)

Fig. 1. Cancer of the Uterus. See page

& 2 (a) cancer cells. } of fluid
" (b) - pus.
(c) cancer cells. (d) fibrous tissue) - c & d are from hard tissue

Fig. 2 (a) cells, (perhaps cancerous.)
(b) cancer cells
(c) fibrous tissue } from hard portion near of uterus
(d). cancerous cells. 450 D.
"

Fig. 3. Cancer of Rectum - See page.
" "

Fig 4 Cancer of Breast. See page
5 & 6. (a) cancer cells from soft part of tumor
(b) - fibrous tissue
(c) - peculiar cells (perhaps glandular) } from hard part of tumor
(d) ~~Ep~~ cancer cells.
"

Fig 5 & 6 } Cancer cells from soft, fungoidal portion of tumor.

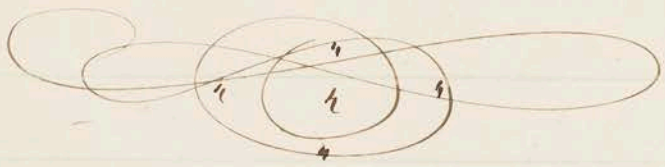

Plate XXI

Fig 1

Fig 2

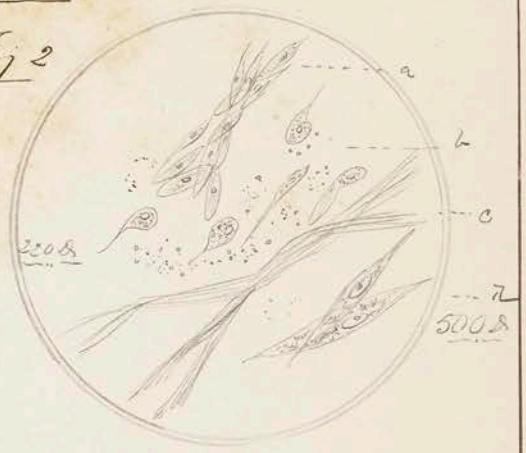

Fig 3

Fig 4

Fig 5

Fig 6

~~To face pl. XXI~~

Fig 1 & 2 — Cancer of Breast — See page

Fig. 1
- a – compound granr cell } fluid of tumor
- b – cancer cells } fluid of tumor
- c – cells from hard portion of tumor.

Fig. 2
- (a) doubtful cells (see text) } from Axillary glands.
- (b) gland cells
- (c) free oil globules
- (d) fibrous tissue (yellow) of nipple
- (e) – fibrous structure of tumor.

"

Fig. 3. Cancer of Breast — See page

"

Fig 4. Epithl tumor of Pelly. See page
showing Epithelial cells & fibrous tissue

"

Plate XXII

Fig 1

Fig 2

Fig 3.

Fig 4

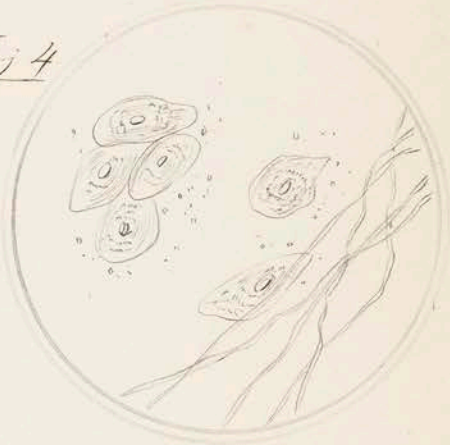

Fig 5

Fig 6